

# **EQUINE DENTITION**

Dr. Prashant Saharan  
Assistant Professor

Department of Livestock Production Management

MJFCVAS  
Chomu



---

# Dental Problems?

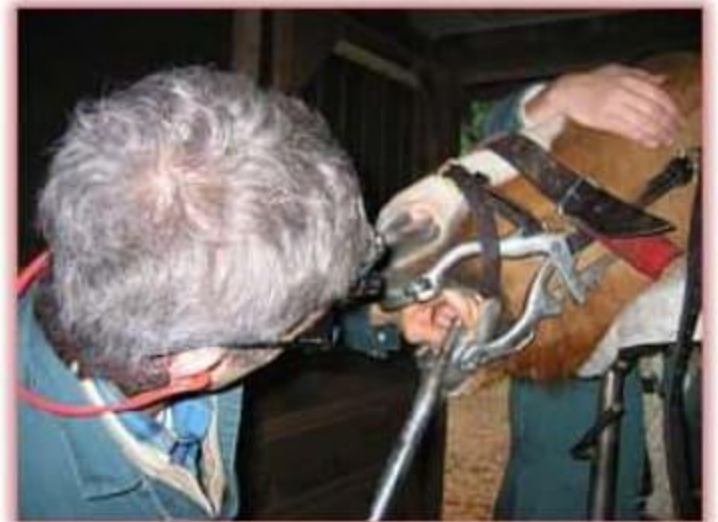- Quidding
  - Spilling/spitting grain or hay
  - Difficulty chewing
  - Cheek sensitivity or swelling
  - Sensitivity to the bit
  - Head shaking or head tilt
  - Foul odor from mouth or nostrils
  - Excess salivation
  - Exaggerated tongue movements
  - Bleeding from mouth (especially after riding)
  - Poor body condition
  - Rough haircoat
-

---



# Dental Examinations

- Probably need to be tranquilized!
- **MUST** use a full-mouth speculum
- Visual and digital examination essential
- How often?



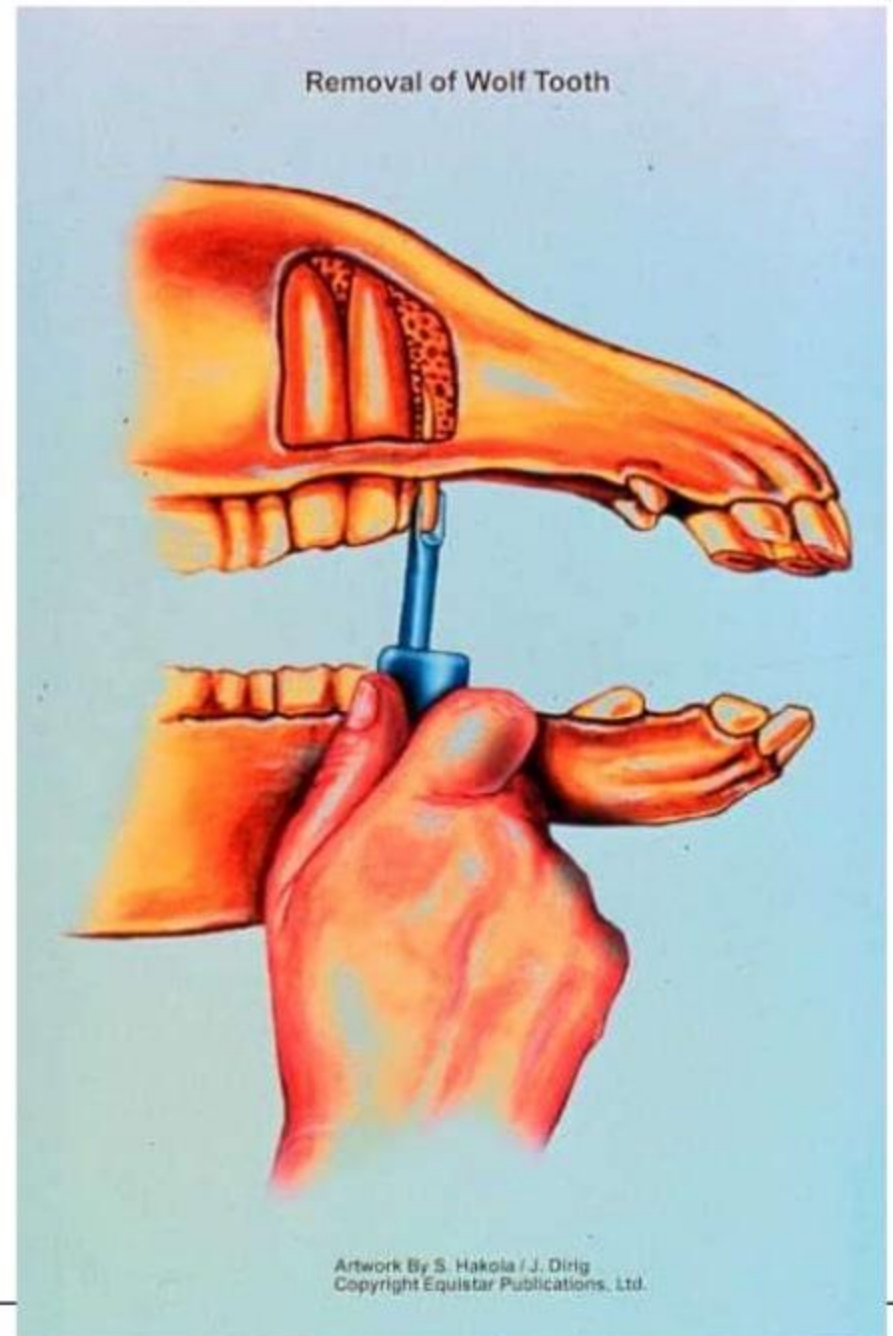


---

# Dental Problems

- Retained dental caps
    - Permanent teeth can't push deciduous teeth out
  - Lampas
    - Swelling in hard palate mucous membrane
  - Two year old bumps
    - Bone reacts with teeth → lump below jaw
  - Wolf teeth
    - Not always next to premolar 2
-

- Wolf tooth location and extraction




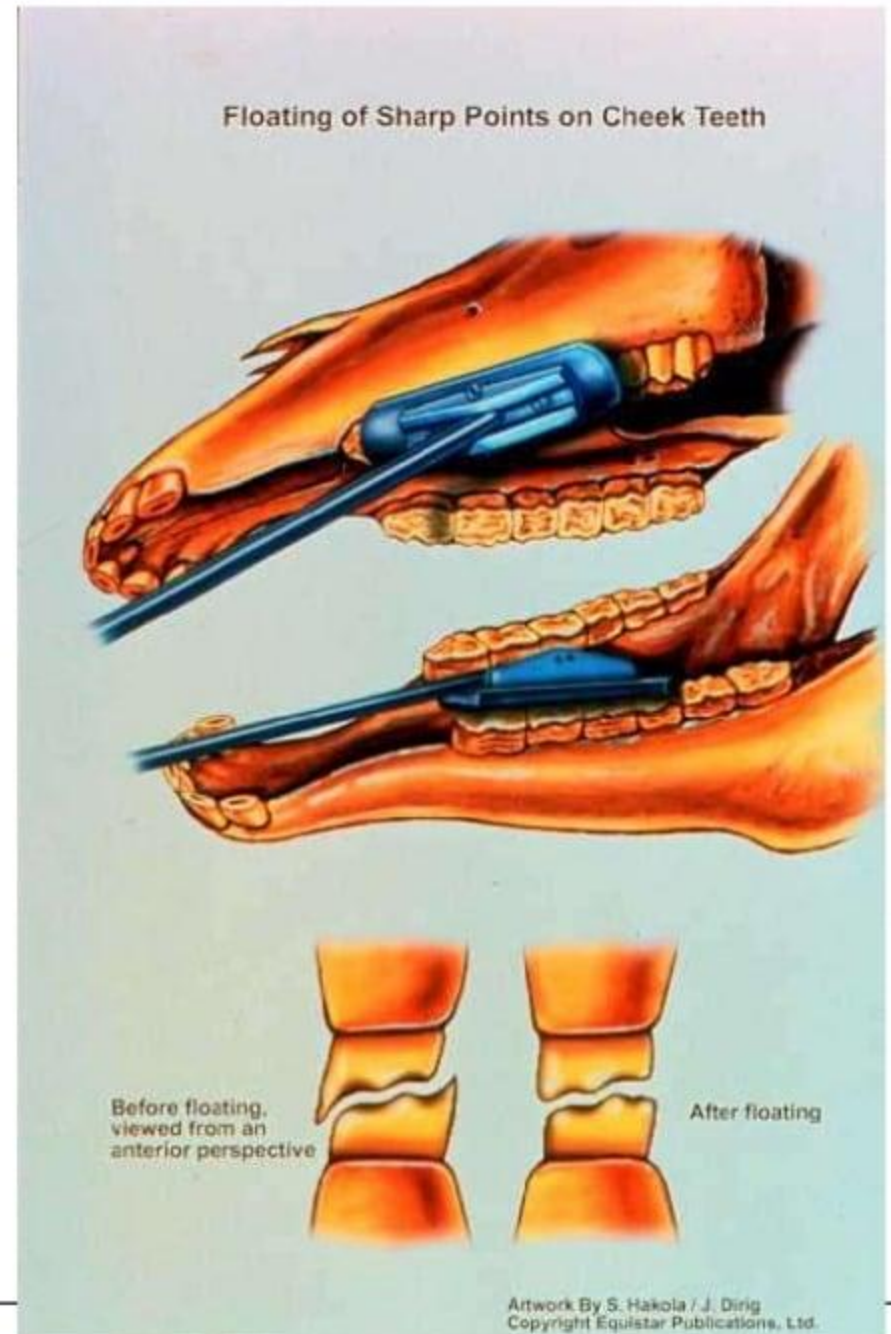


---

# Dental Problems

- Canines
    - Don't always erupt
  - Molar hooks
    - Upper premolar 2
    - Lower third molar (most painful)
    - Float inside lower jaw, outside of upper jaw
  - Cribbing (woodchewing)
    - Air isn't swallowed!
-

- 
- Floating the teeth to get rid of sharp points on molars and premolars
    - Outside of upper teeth
    - Inside of lower teeth





---

# Dental Problems

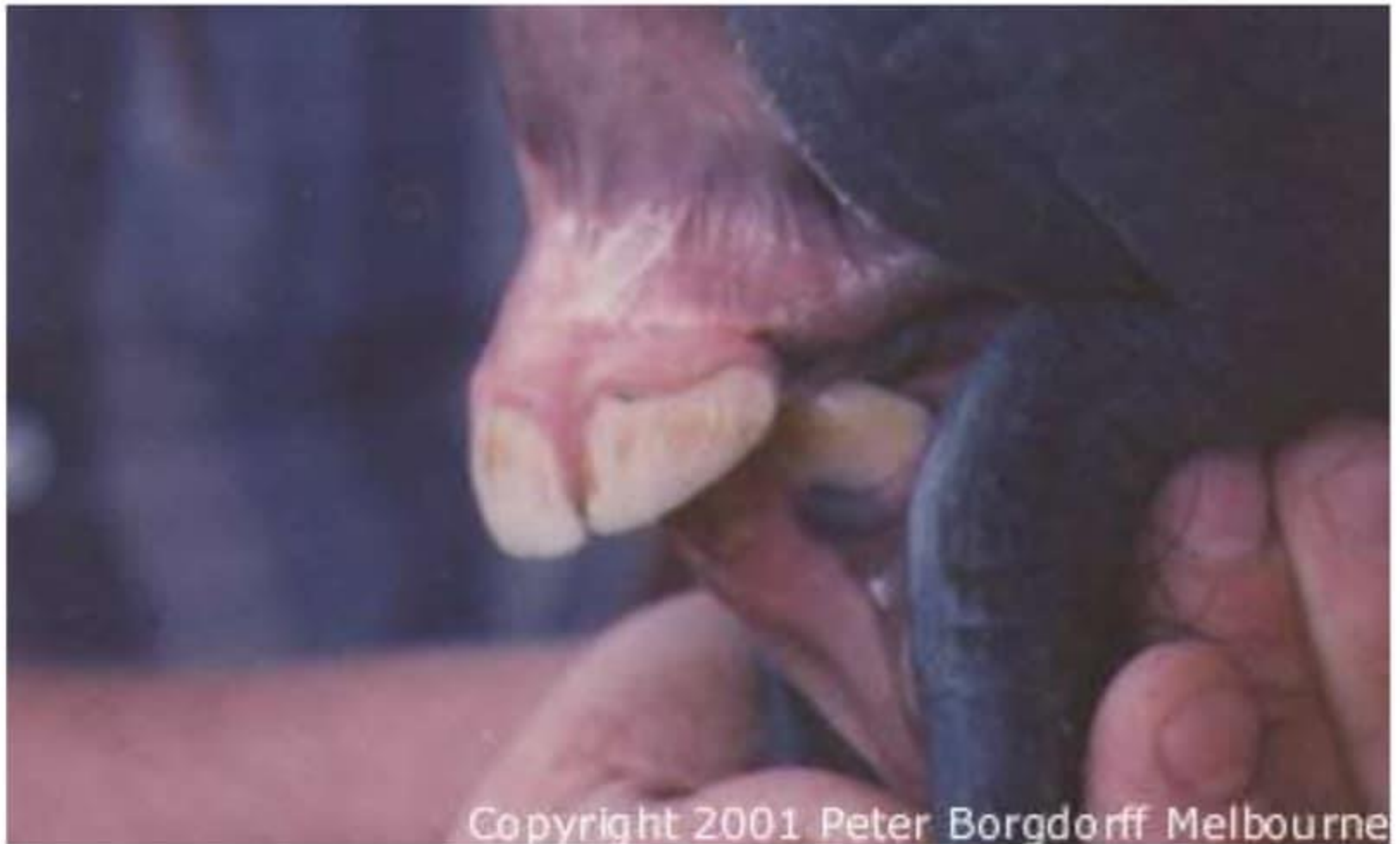- Windsucking (Stumpsucking)
    - Similar to Cribbing but doesn't require something to set teeth on
    - May cause colic
    - Overdevelopment of neck muscles
  
  - Parrot Mouth/overshot jaw
    - Increased incidence of molar hooks
    - Decreased ability to prehend food
-



---



# Parrot Mouth

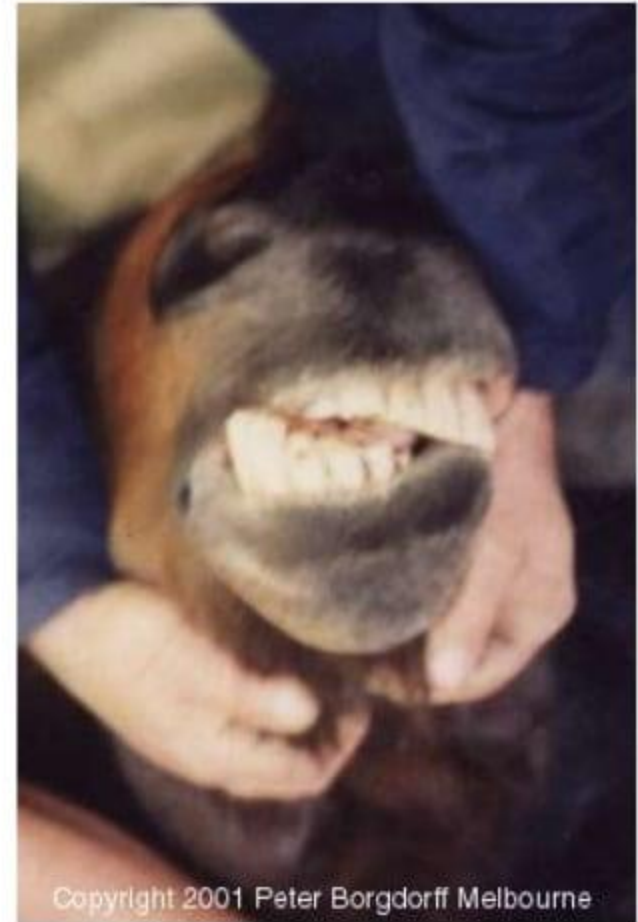


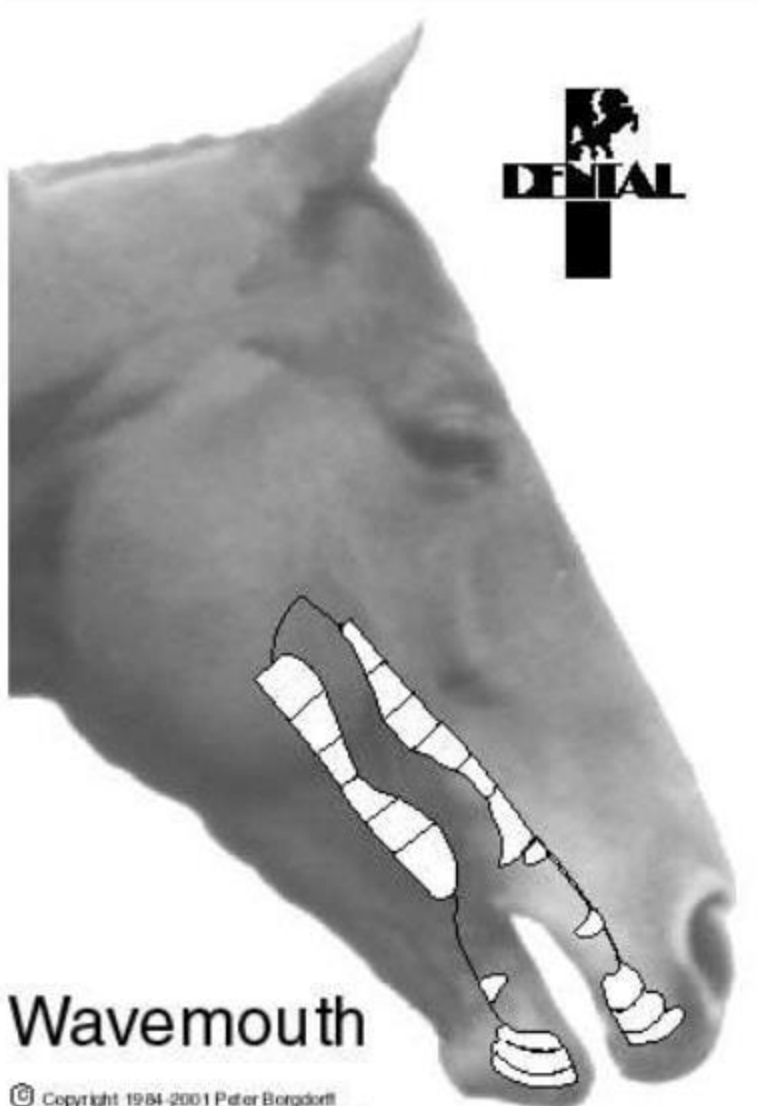
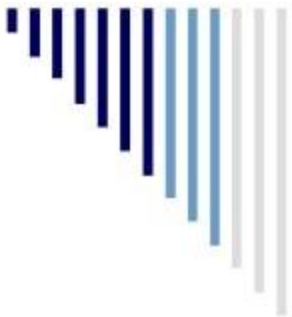Copyright 2001 Peter Borgdorff Melbourne

---

# Dental Problems

- Monkey Mouth/undershot jaw
- Wave Mouth
  - Can be caused by retained cap
  - Uneven wear of premolars and molars
- Step mouth
  - Missing teeth/uneven wear
- Cracked or fractured teeth





**DENTAL**

# Wavemouth

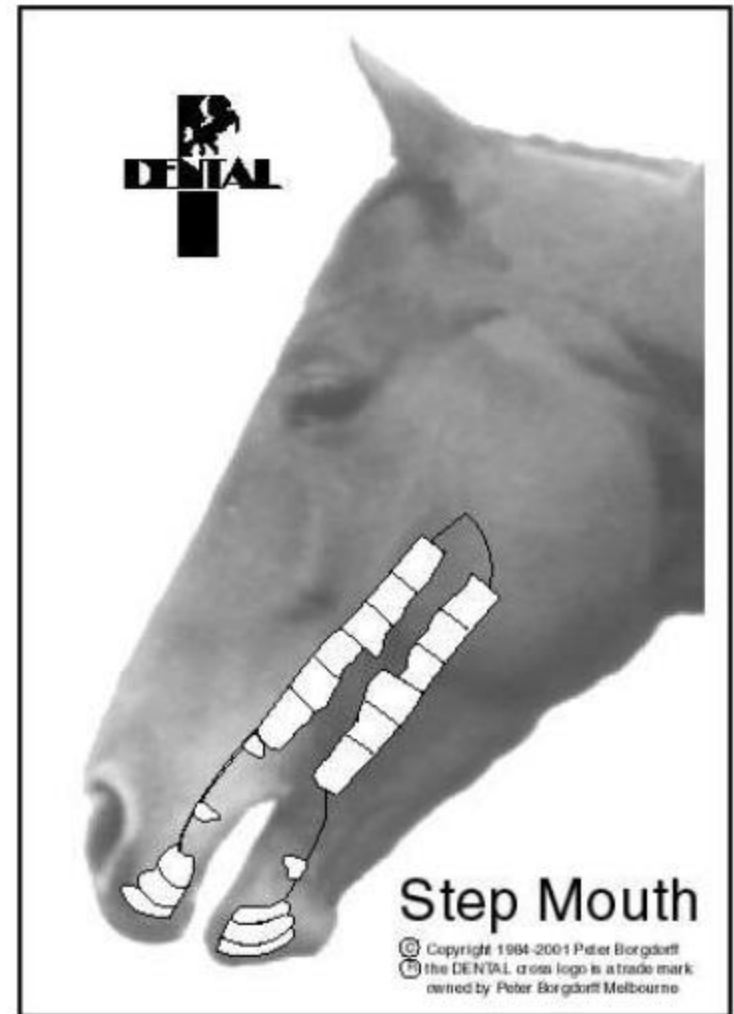
© Copyright 1984-2001 Peter Borgdorff  
the DENTAL cross logo is a trade mark  
owned by Peter Borgdorff Melbourne

The image shows a profile of a horse's head. In the upper right area of the head, there is a black cross logo with a silhouette of a horse and rider in the top-left quadrant and the word "DENTAL" in a bold, sans-serif font across the horizontal bar. Below the horse's mouth, there is a white diagram of the horse's teeth, showing the upper and lower dental arches with individual teeth outlined in black. The horse's name "Wavemouth" is printed in a large, bold, sans-serif font below the diagram. At the bottom left of the image frame, there is a copyright notice: "© Copyright 1984-2001 Peter Borgdorff the DENTAL cross logo is a trade mark owned by Peter Borgdorff Melbourne".



# Dental Problems

- Periodontal disease
- Dental decay
- Tooth root abscess
- Supernumerary teeth
- Dentigerous cyst
- Salivary duct injuries
- Tongue lacerations
- Oral ulcers



---



# Dental Problems

- Cleft Palate
  - Odontomas
  - Bishoping
-



# Dysphagia

Inability to prehend, chew and swallow properly

- Difficulty or unwillingness to eat
  - Slow and messy feeding
  - Extreme bad breath
  - Quidding
  - Productive cough
  - Nasal reflux of saliva, food and fluids
- Possible Causes:
    - Strangles infection
    - Stylohyoid osteomyelitis
    - Physical trauma
    - Poisoning, such as lead
    - Botulism
-

