

EQUINE DENTITION

Dr. Prashant Saharan
Assistant Professor

Department of Livestock Production Management

MJFCVAS
Chomu




Permanent Teeth

- Replace the deciduous teeth, where present
 - The deciduous tooth that precedes the permanent tooth is called a **cap**
 - From eruption to being in wear is ~6 months
 - Continue to grow, using up the reserve crown over many years
 - Adult stallion with wolf teeth has **42** teeth
-

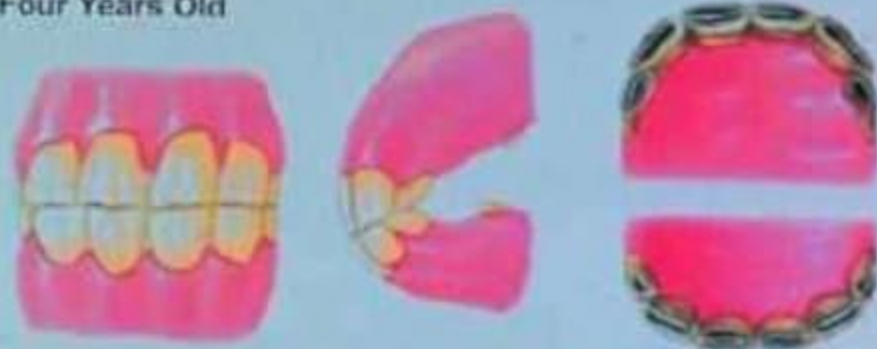
Determination of the Horse's Age

Artwork By S. Hakola
Copyright Equistar Publications, Ltd.

One Year Old



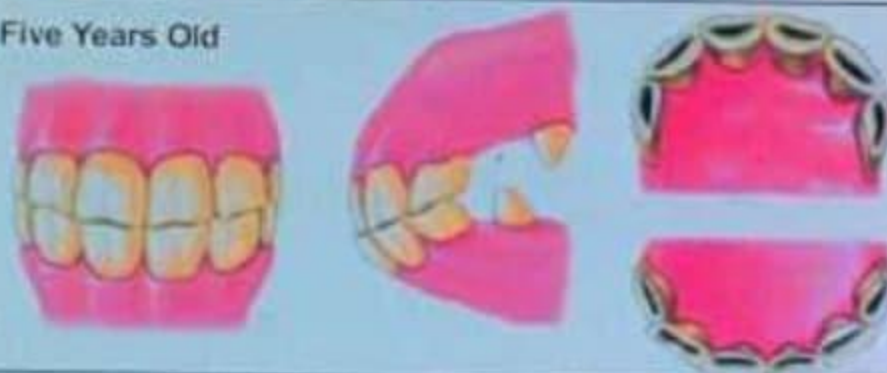
Four Years Old



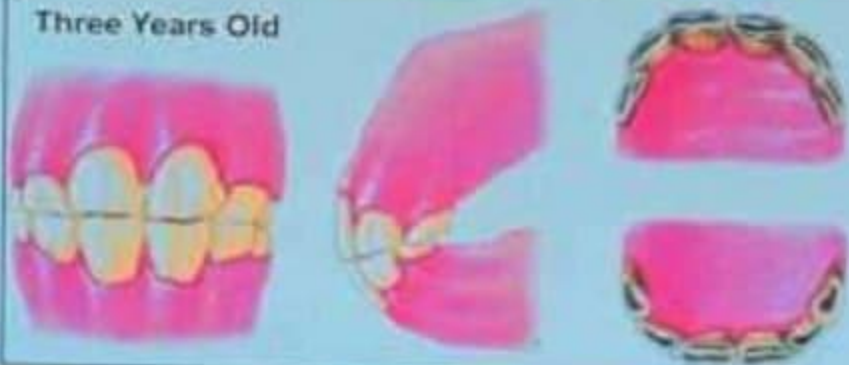
Two Years Old




Five Years Old



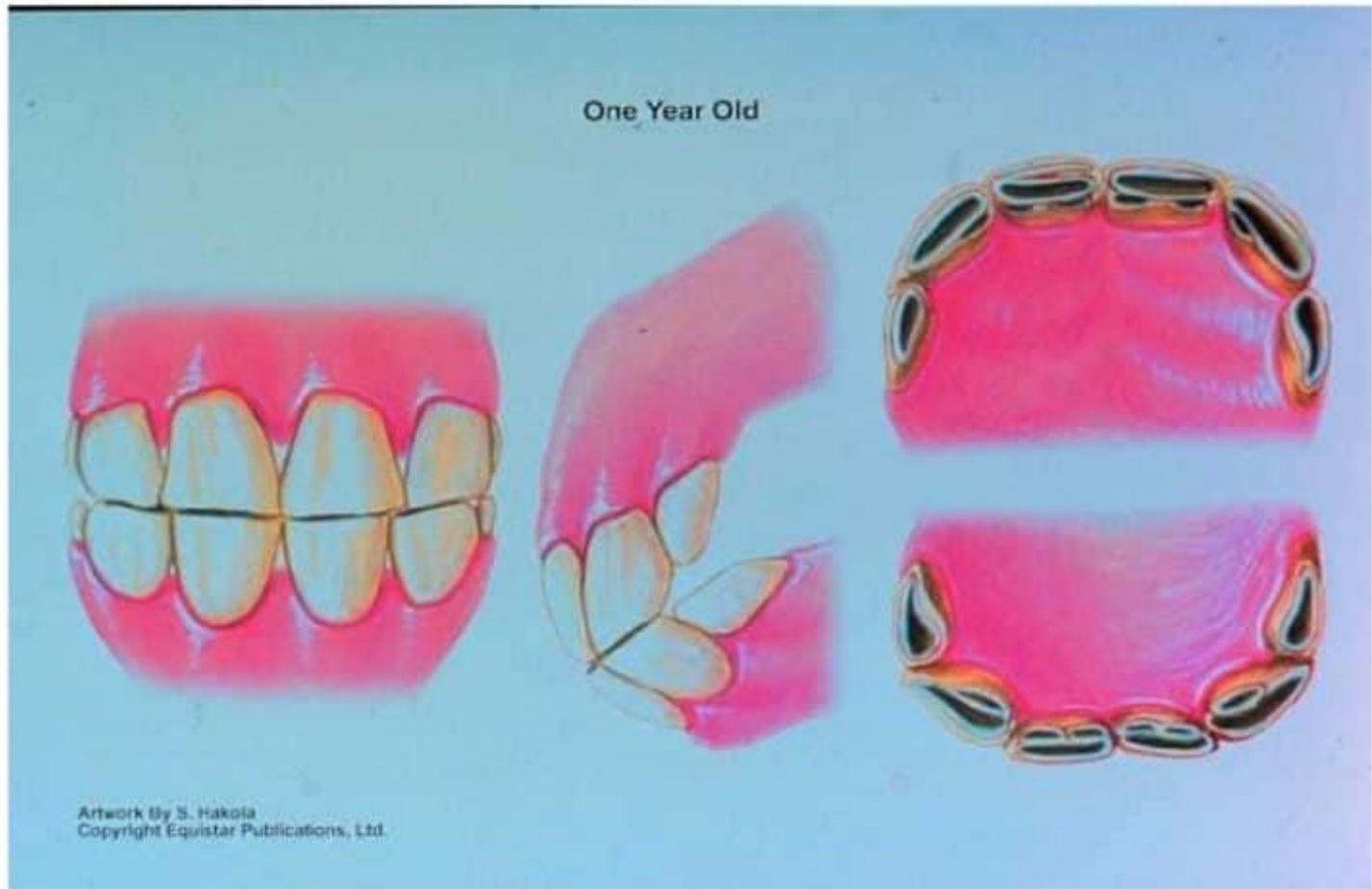
Three Years Old



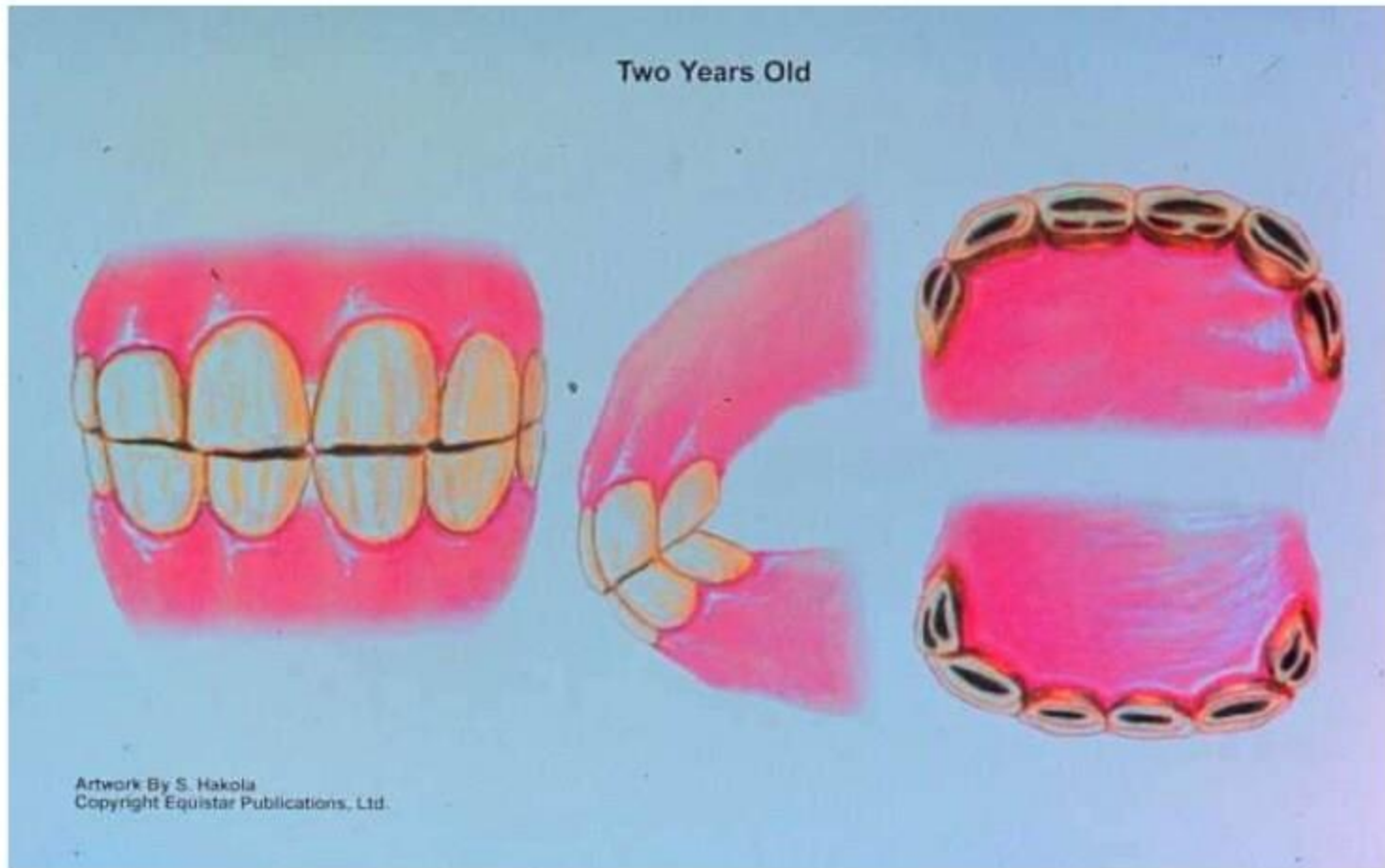
Six Years Old



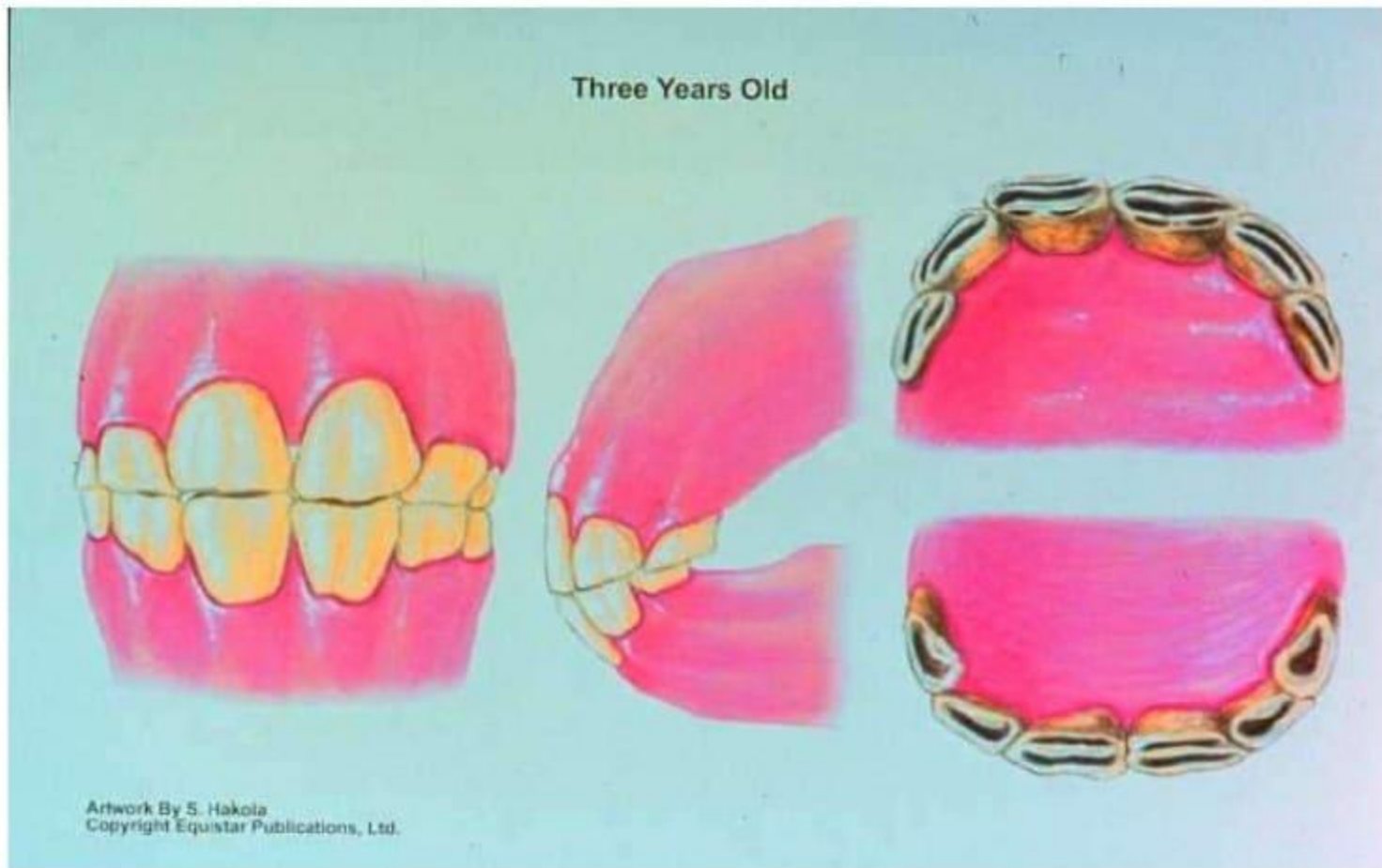
One Year Old



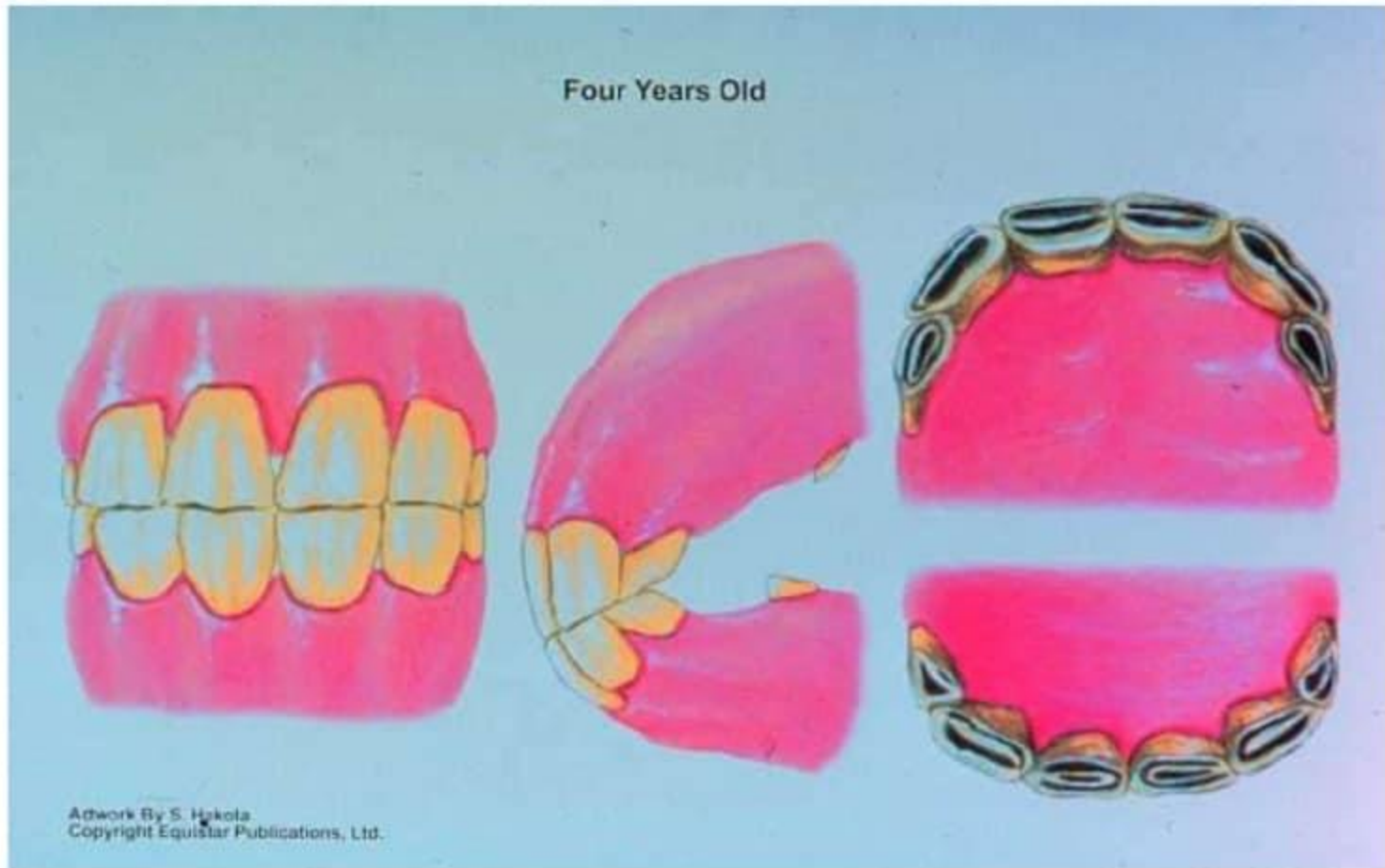
Two Years Old



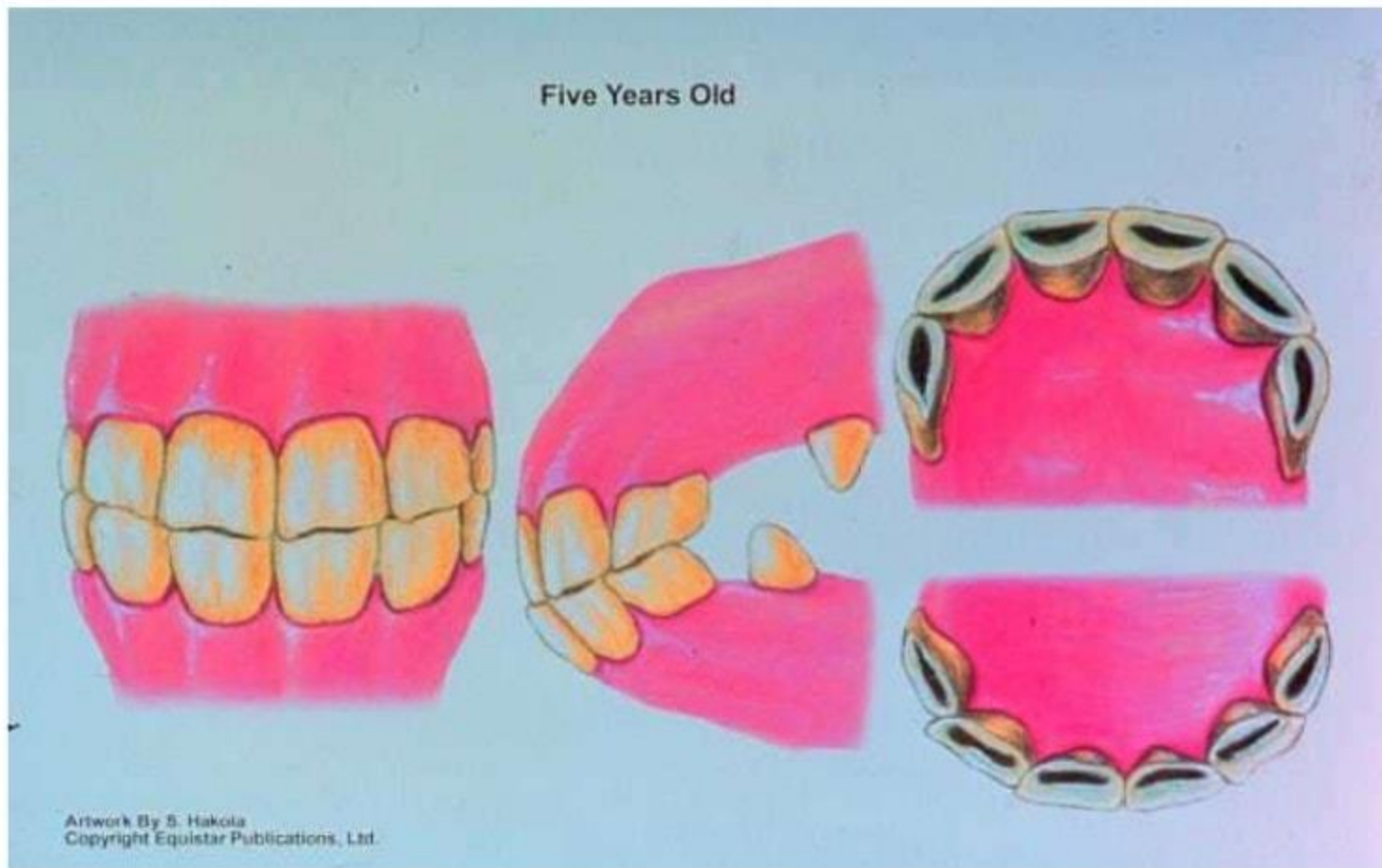
Three Years Old



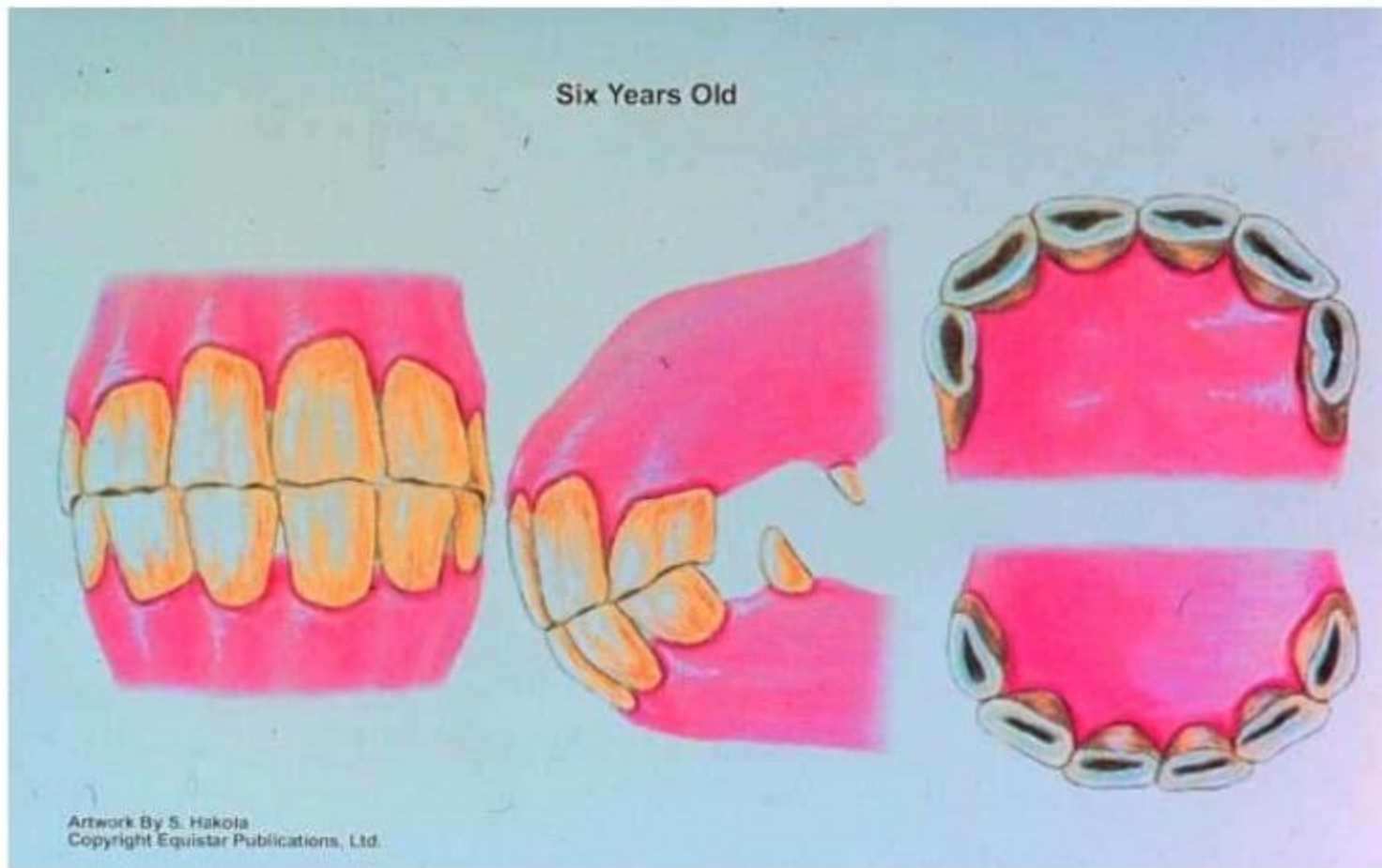
Four Years Old



Five Years Old

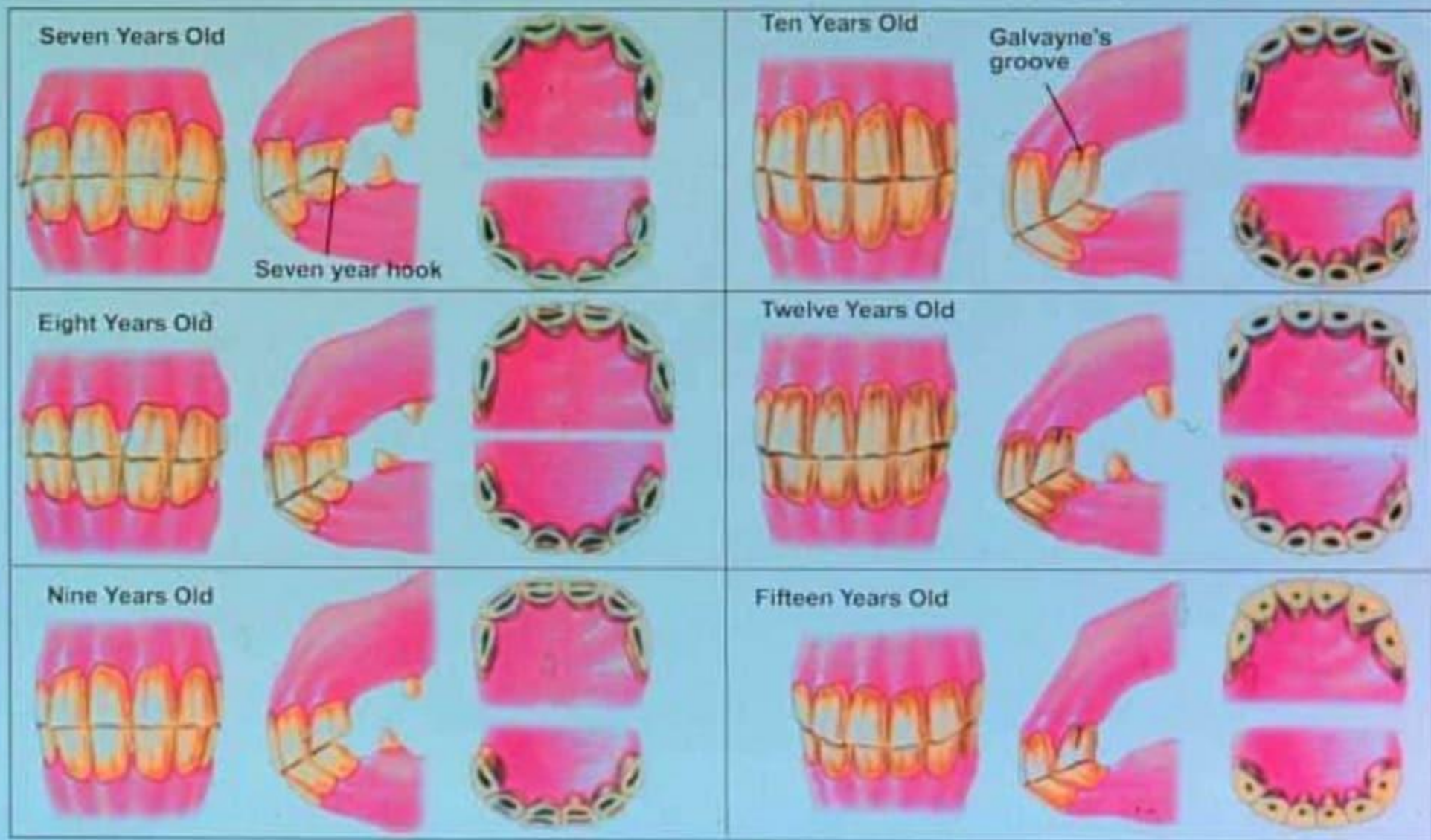


Six Years Old

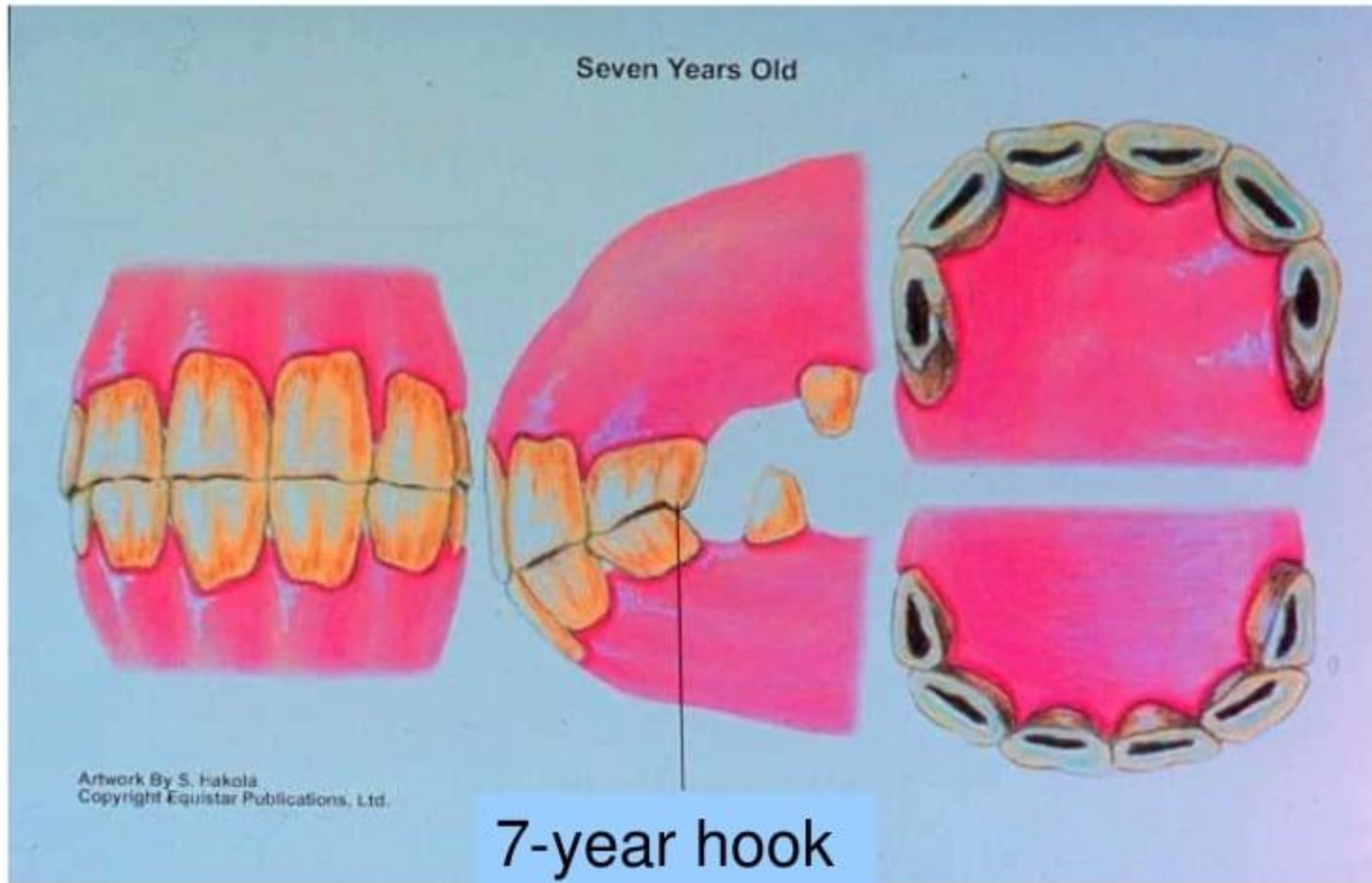


Determination of the Horse's Age

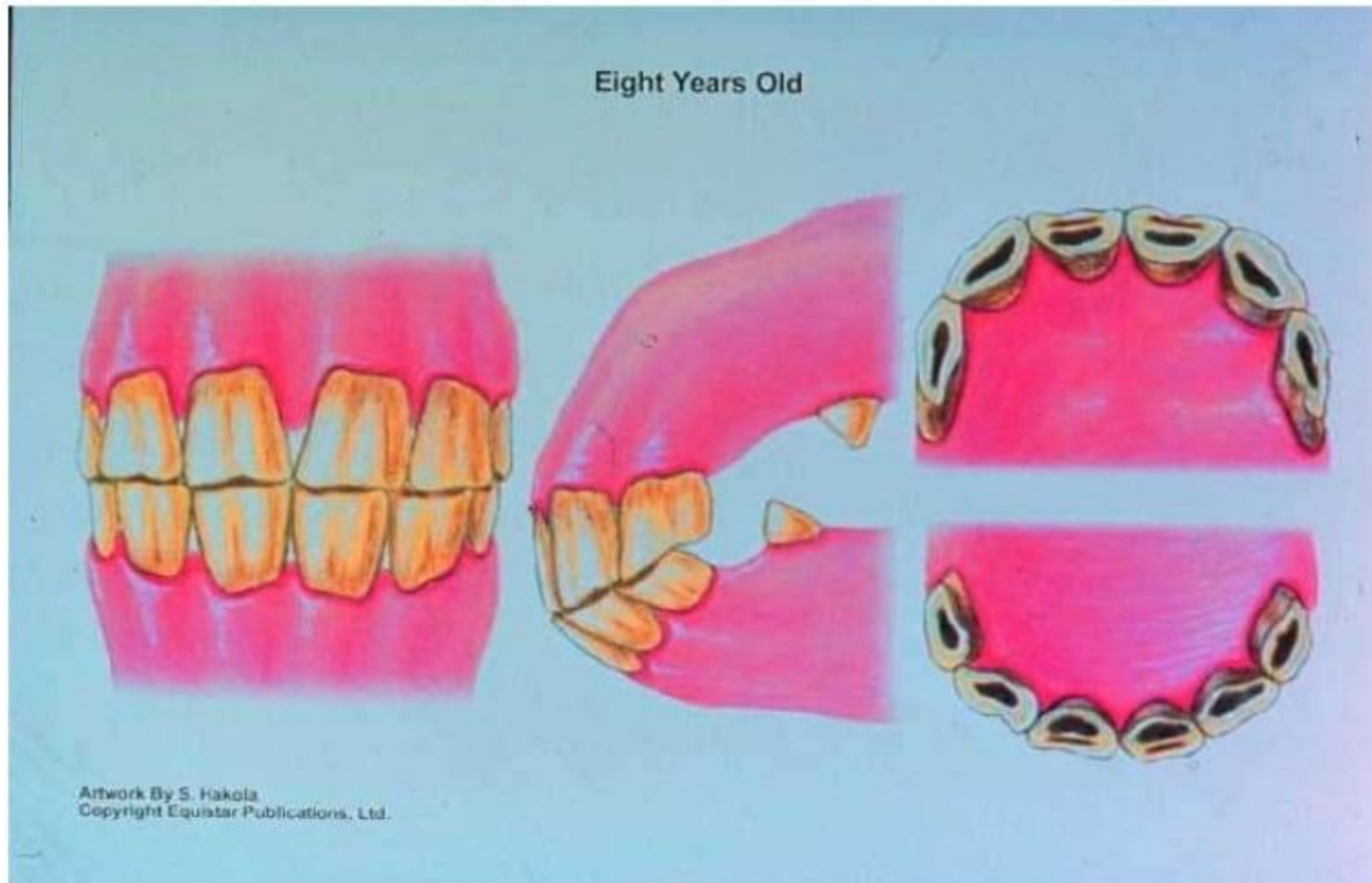Artwork By S. Hakola
Copyright Equistar Publications, Ltd.



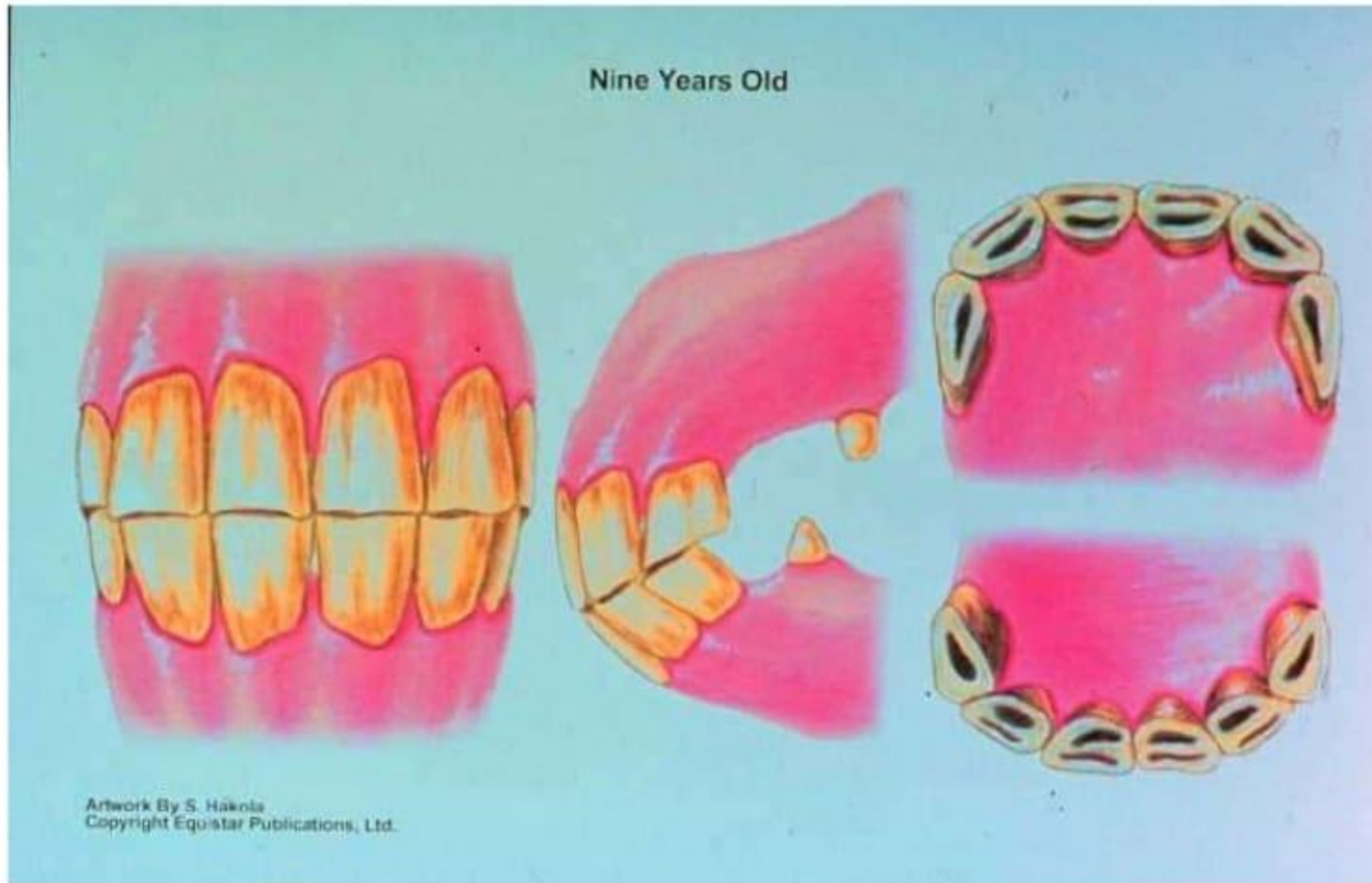Seven Years Old



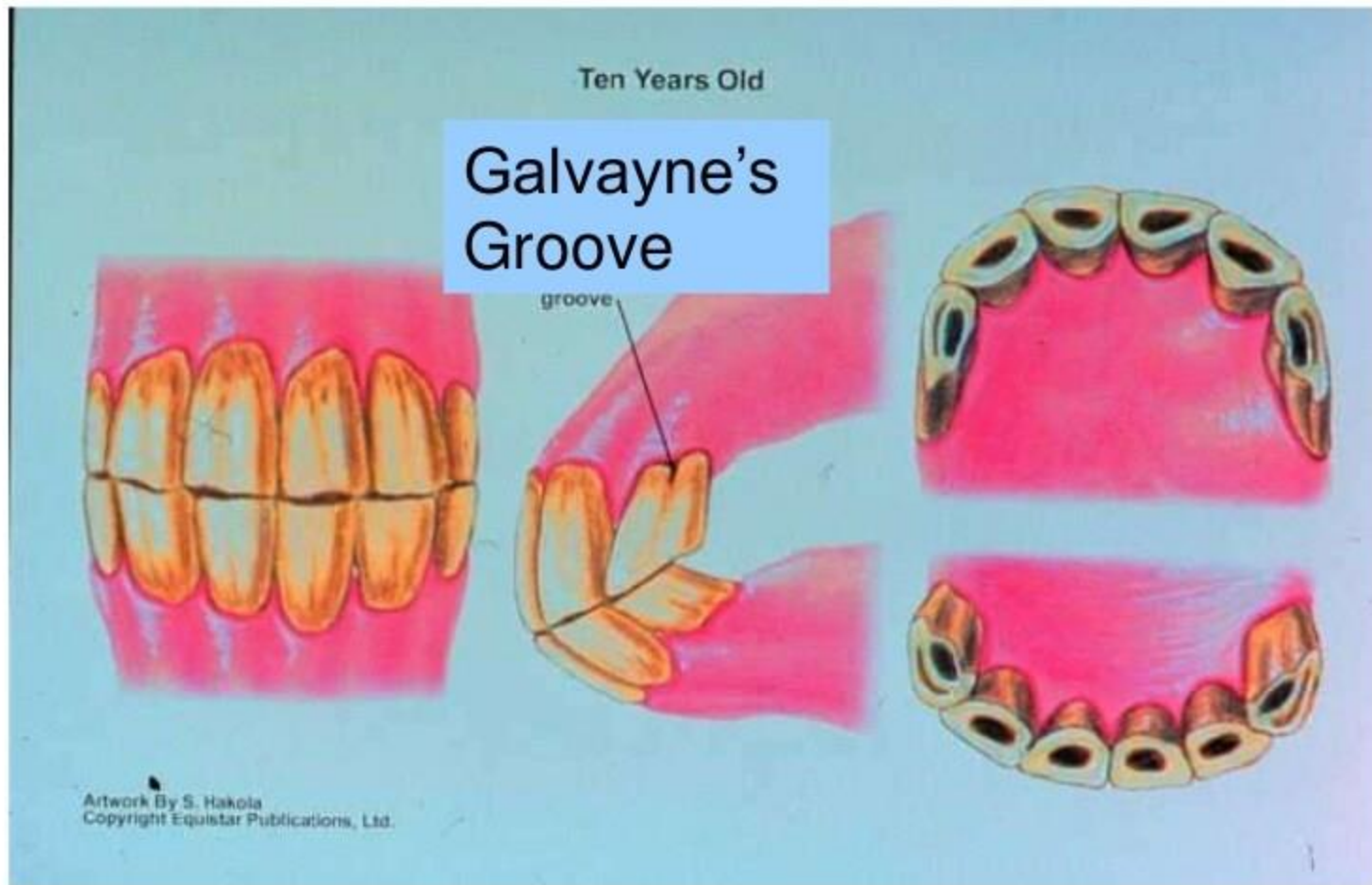
Eight Years Old



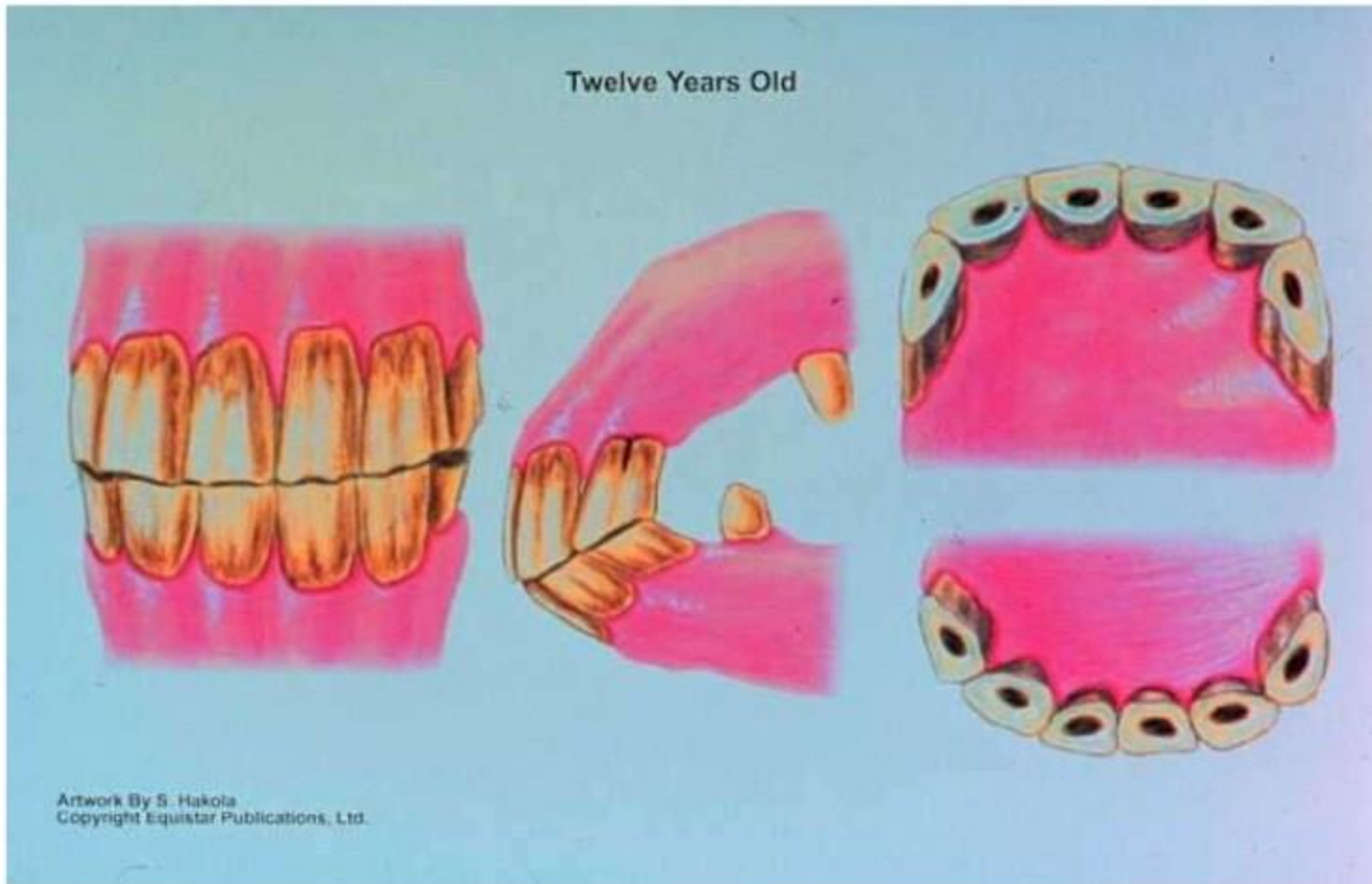
Nine Years Old



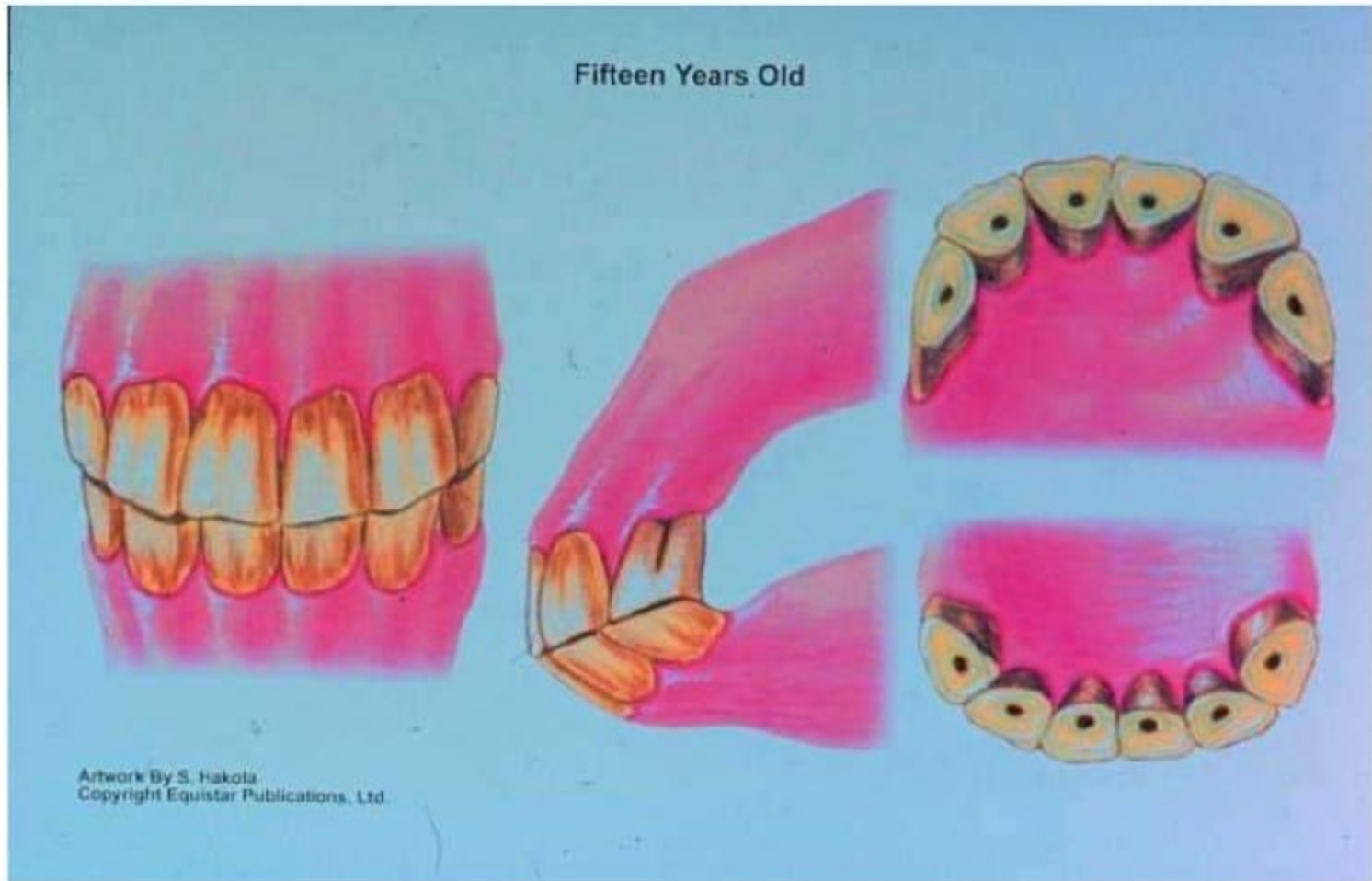Ten Years Old



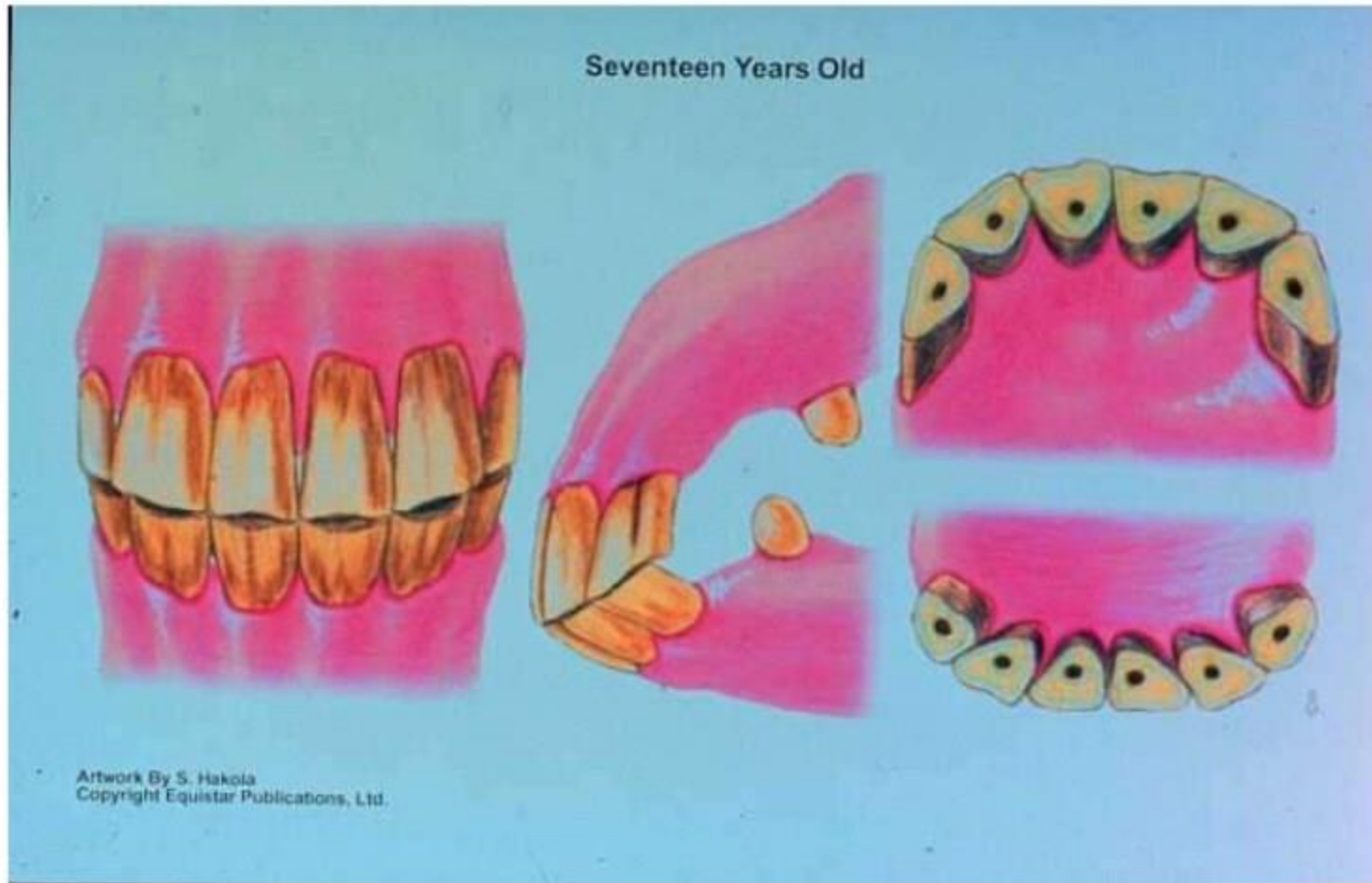
Twelve Years Old



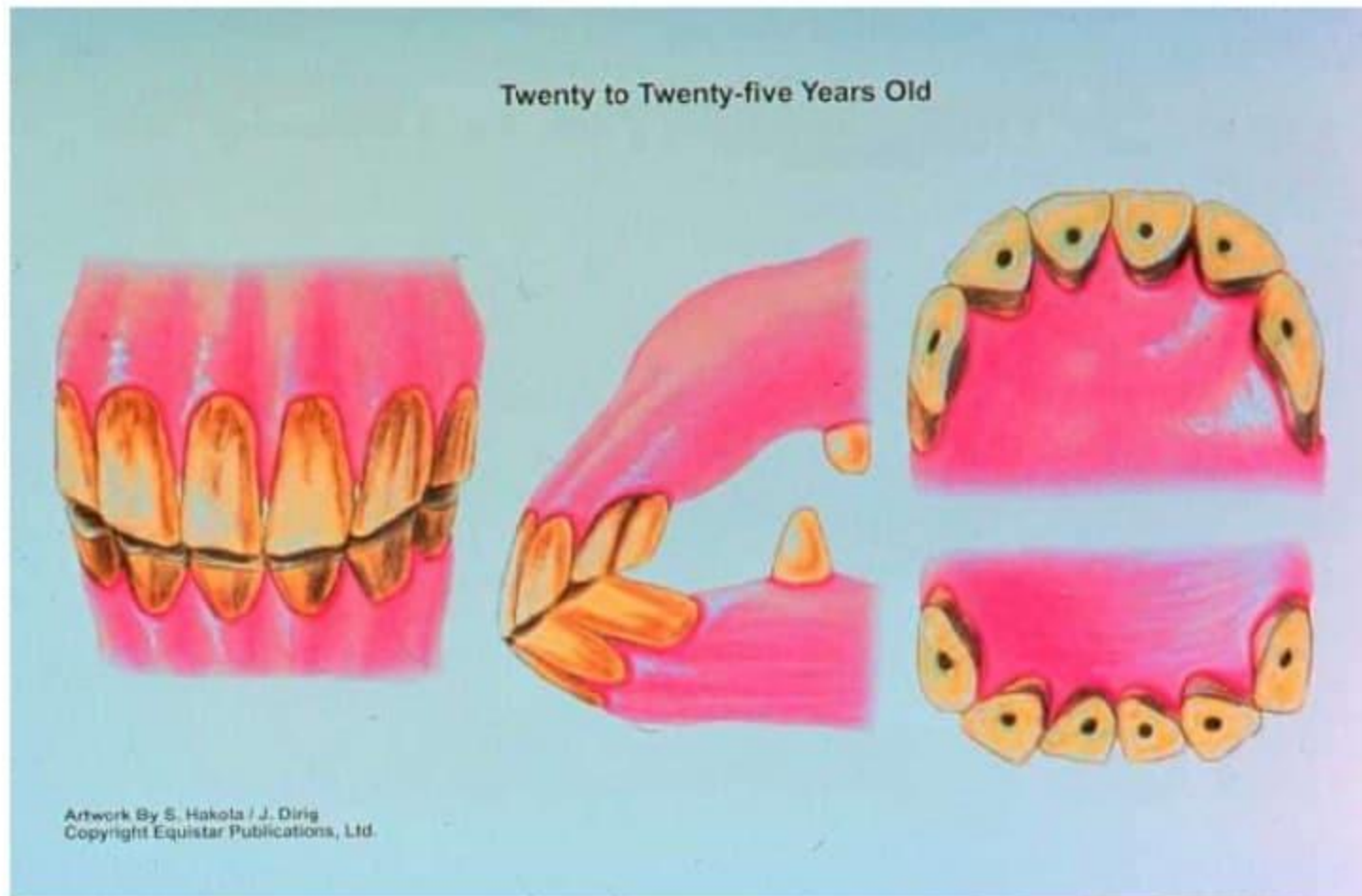
Fifteen Years Old



Seventeen Years Old



Twenty Years Old and Older





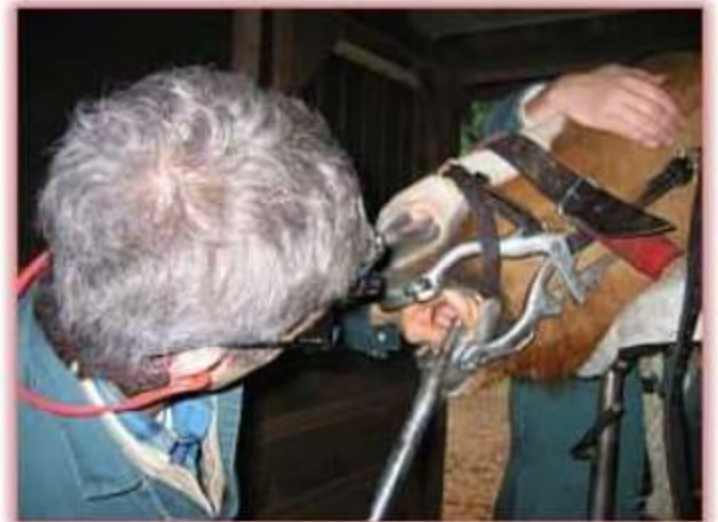Dental Problems?

- Quidding
 - Spilling/spitting grain or hay
 - Difficulty chewing
 - Cheek sensitivity or swelling
 - Sensitivity to the bit
 - Head shaking or head tilt
 - Foul odor from mouth or nostrils
 - Excess salivation
 - Exaggerated tongue movements
 - Bleeding from mouth (especially after riding)
 - Poor body condition
 - Rough haircoat
-



Dental Examinations

- Probably need to be tranquilized!
- **MUST** use a full-mouth speculum
- Visual and digital examination essential
- How often?

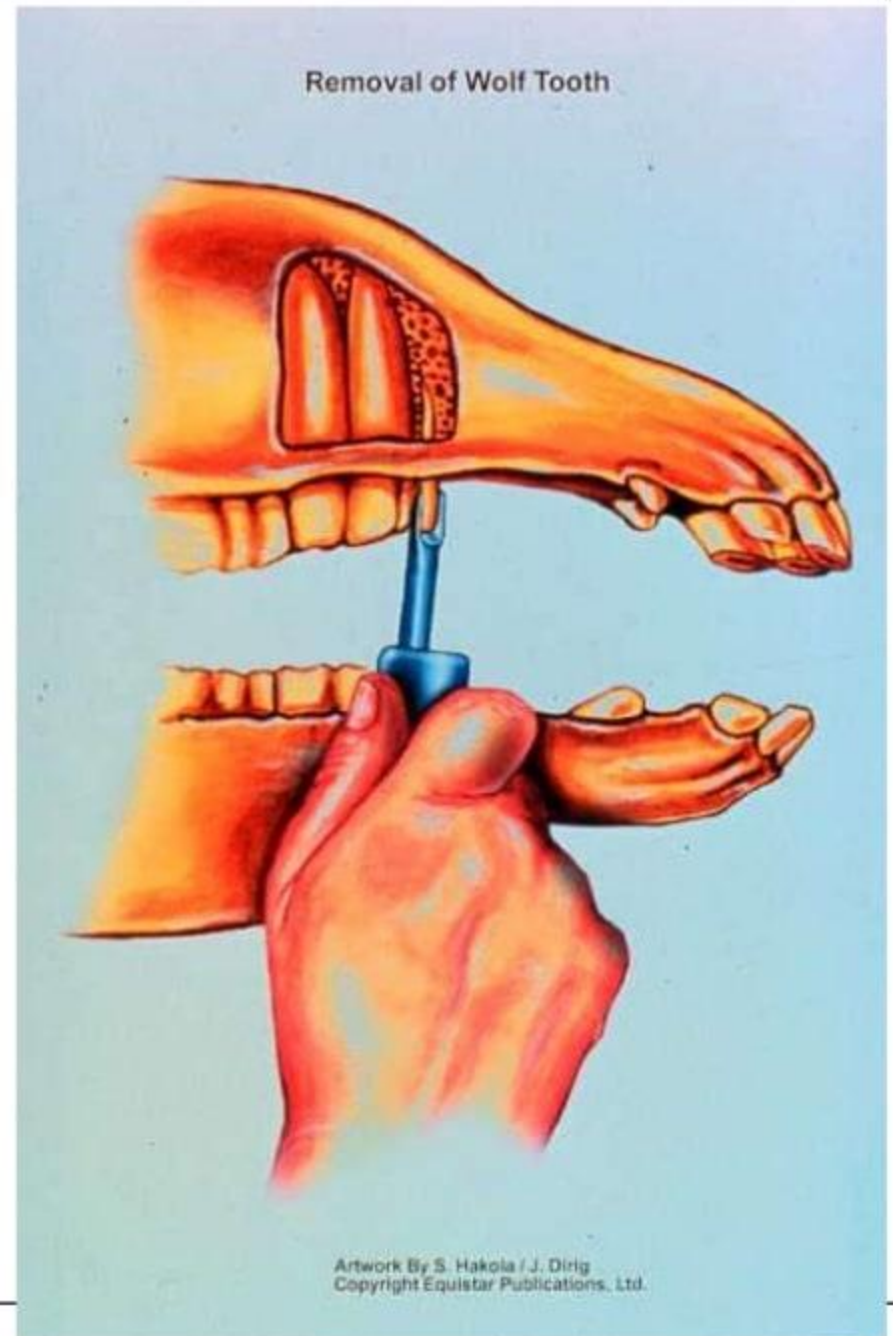




Dental Problems

- Retained dental caps
 - Permanent teeth can't push deciduous teeth out
 - Lampas
 - Swelling in hard palate mucous membrane
 - Two year old bumps
 - Bone reacts with teeth → lump below jaw
 - Wolf teeth
 - Not always next to premolar 2
-


- Wolf tooth location and extraction

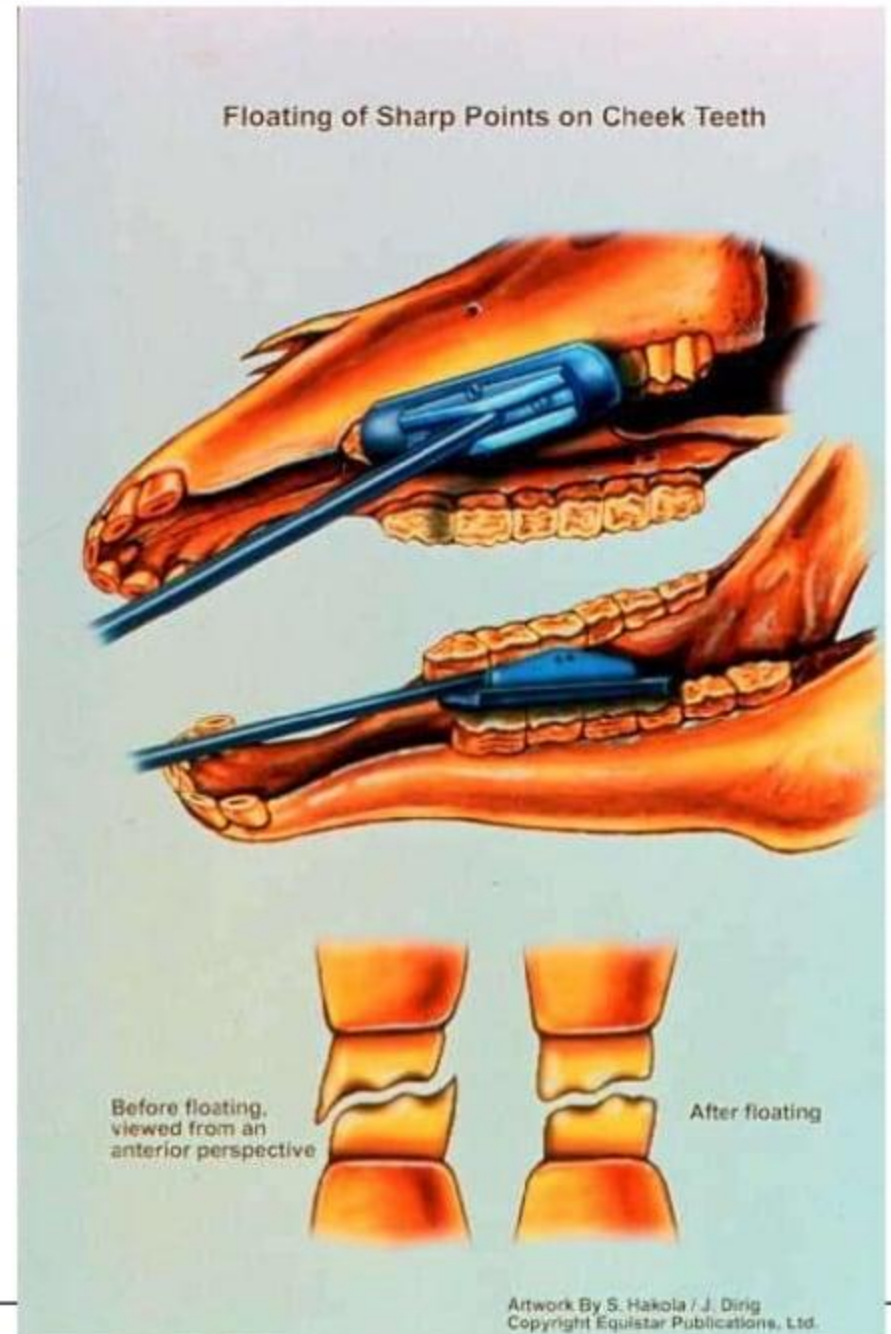




Dental Problems

- Canines
 - Don't always erupt
 - Molar hooks
 - Upper premolar 2
 - Lower third molar (most painful)
 - Float inside lower jaw, outside of upper jaw
 - Cribbing (woodchewing)
 - Air isn't swallowed!
-

- 
- Floating the teeth to get rid of sharp points on molars and premolars
 - Outside of upper teeth
 - Inside of lower teeth





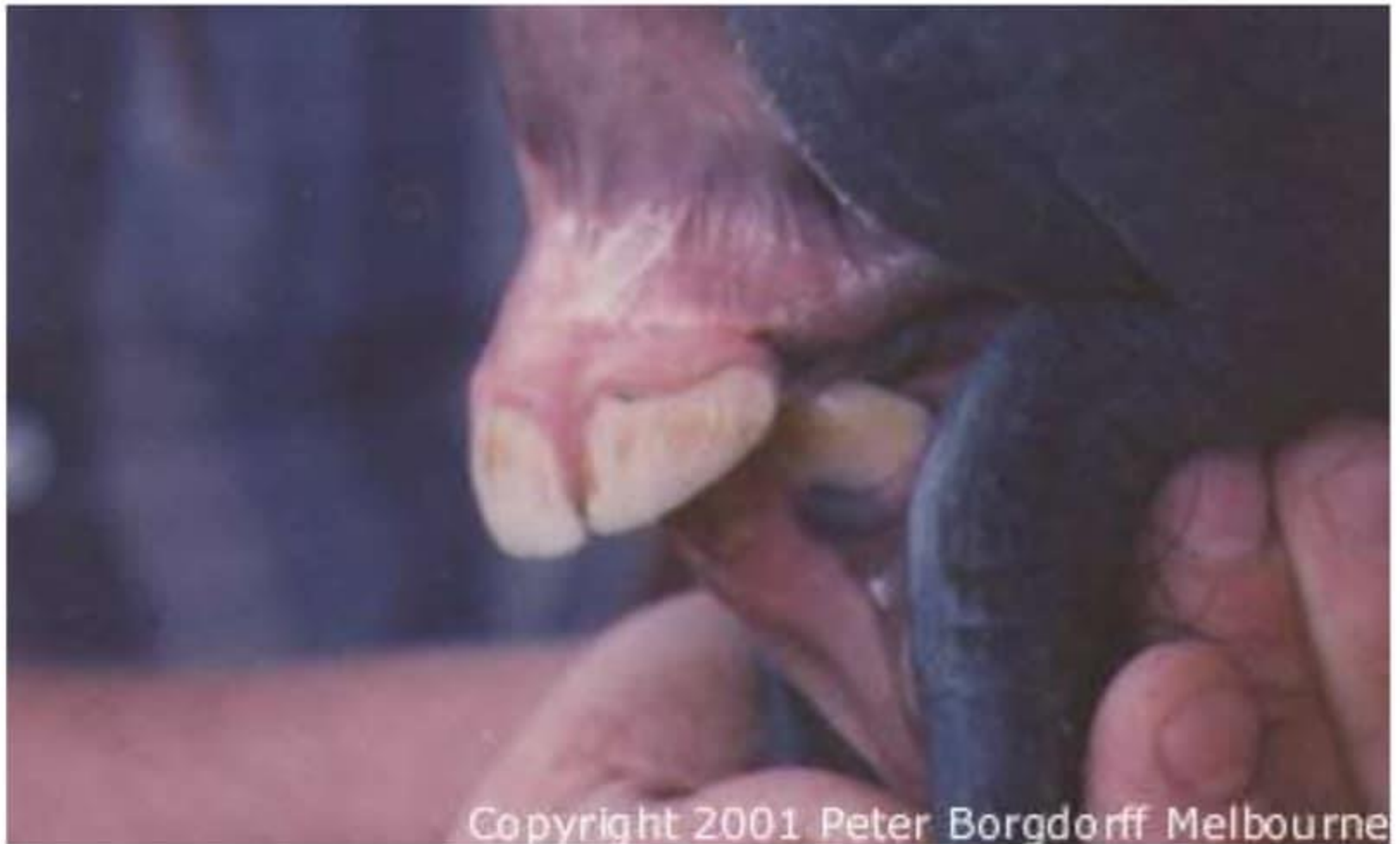Dental Problems

- Windsucking (Stumpsucking)
 - Similar to Cribbing but doesn't require something to set teeth on
 - May cause colic
 - Overdevelopment of neck muscles

 - Parrot Mouth/overshot jaw
 - Increased incidence of molar hooks
 - Decreased ability to prehend food
-



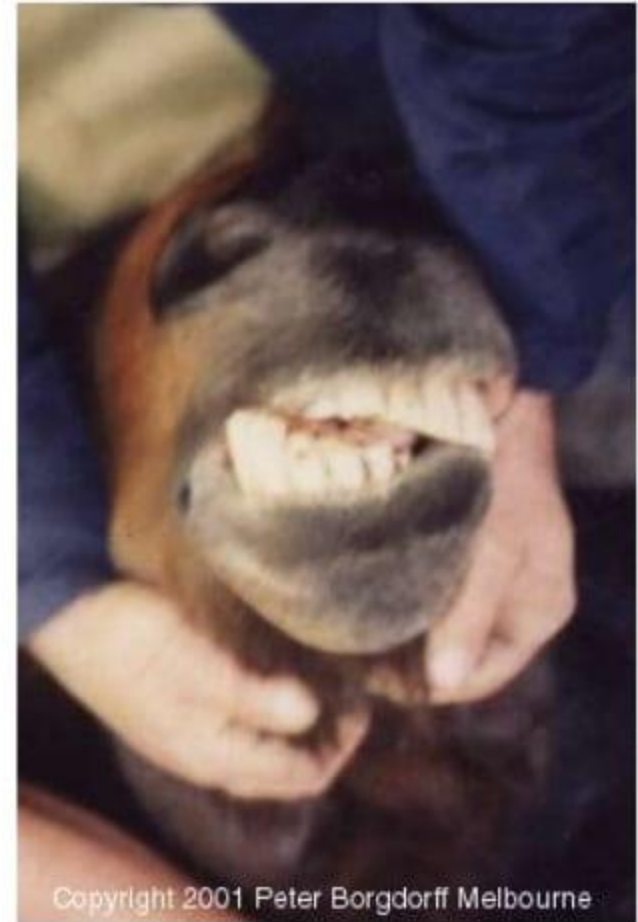
Parrot Mouth

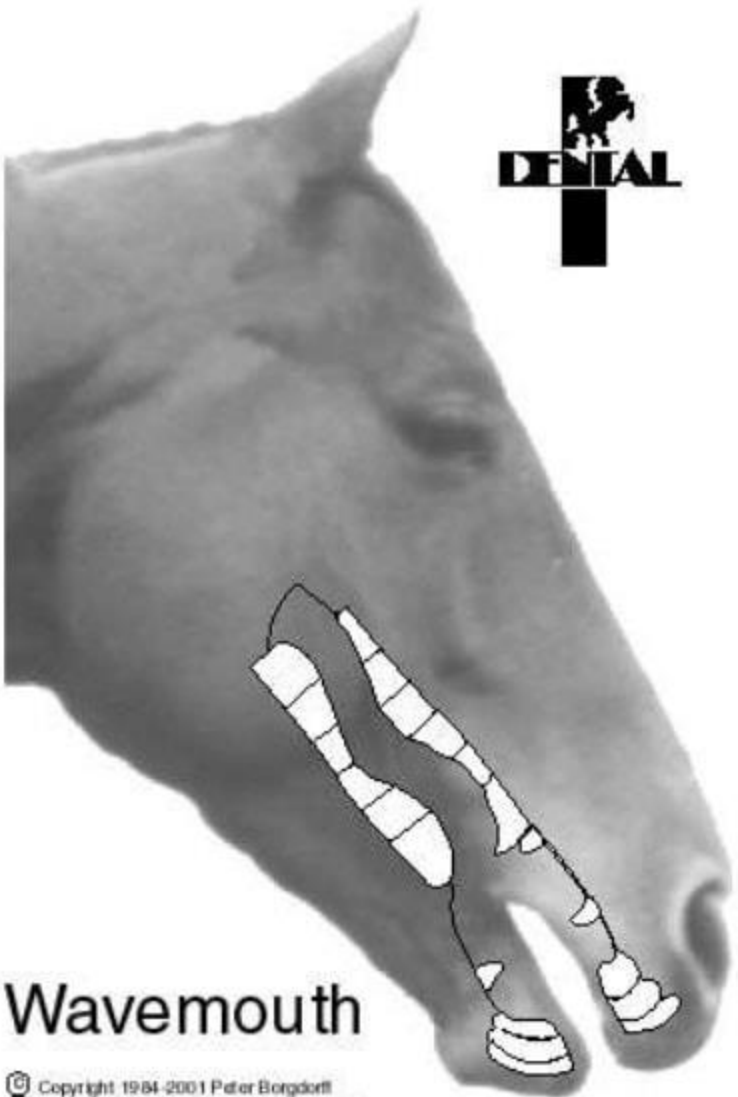
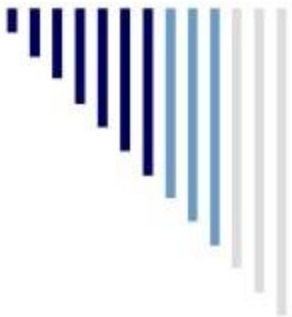

Copyright 2001 Peter Borgdorff Melbourne

Dental Problems

- Monkey Mouth/undershot jaw
- Wave Mouth
 - Can be caused by retained cap
 - Uneven wear of premolars and molars
- Step mouth
 - Missing teeth/uneven wear
- Cracked or fractured teeth





DENTAL

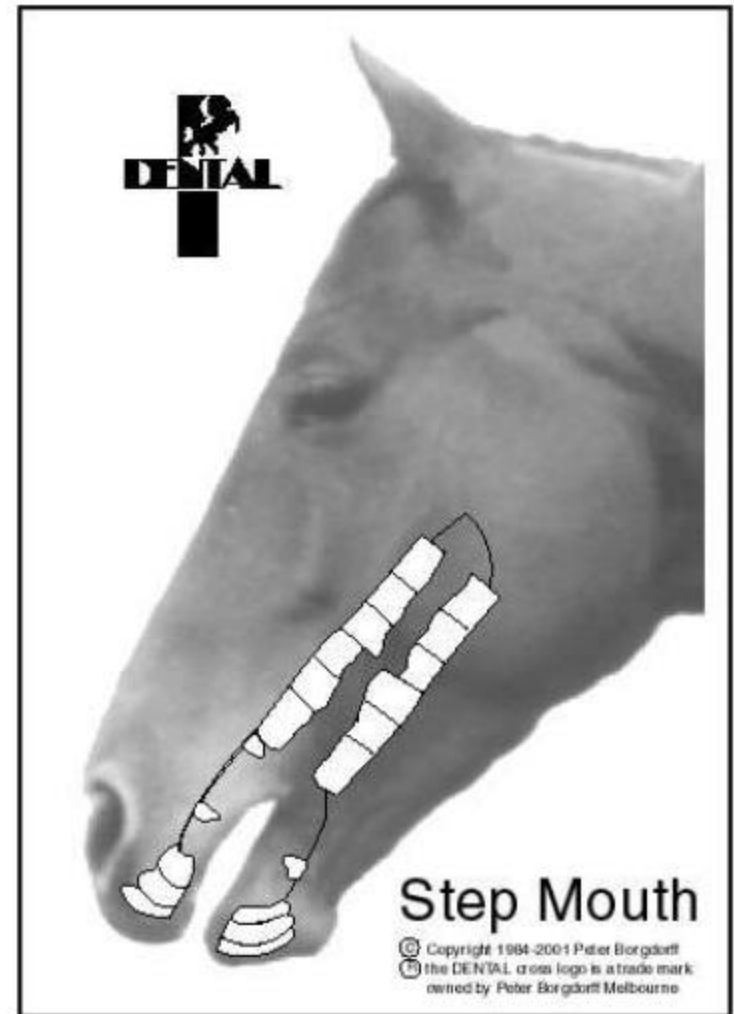
Wavemouth

© Copyright 1984-2001 Peter Borgdorff
the DENTAL cross logo is a trade mark
owned by Peter Borgdorff Melbourne

The image shows a horse's head in profile, facing right. A black dental cross logo is positioned in the upper right area of the horse's face. The logo consists of a cross with a silhouette of a horse's head in the top-left quadrant and the word "DENTAL" in a bold, sans-serif font across the horizontal bar. Below the horse's mouth, a white diagram illustrates the dental arches, showing the arrangement of the teeth. The horse's name, "Wavemouth", is printed in a large, bold, sans-serif font at the bottom left of the image. At the bottom left, there is a copyright notice: "© Copyright 1984-2001 Peter Borgdorff the DENTAL cross logo is a trade mark owned by Peter Borgdorff Melbourne".

Dental Problems

- Periodontal disease
- Dental decay
- Tooth root abscess
- Supernumerary teeth
- Dentigerous cyst
- Salivary duct injuries
- Tongue lacerations
- Oral ulcers





Dental Problems

- Cleft Palate
 - Odontomas
 - Bishoping
-



Dysphagia

Inability to prehend, chew and swallow properly

- Difficulty or unwillingness to eat
 - Slow and messy feeding
 - Extreme bad breath
 - Quidding
 - Productive cough
 - Nasal reflux of saliva, food and fluids
- Possible Causes:
 - Strangles infection
 - Stylohyoid osteomyelitis
 - Physical trauma
 - Poisoning, such as lead
 - Botulism
-

