


# EQUINE DENTITION

Dr. Prashant Saharan  
Assistant Professor

Department of Livestock Production Management

MJFCVAS  
Chomu

---



# “Never Look a Gift Horse in the Mouth”

- Aging a horse by teeth
  - Diseases of the teeth
  - Diseases of the oral cavity
-



---

# Teeth

- **Incisors** – cutting teeth, closest to the front of the mouth
  - **Canines** – common in adult males, less common and smaller in adult females
    - Found in the gap between the incisors and premolars
  - **Premolars** – the three or four cheek teeth closest to front of mouth
  - **Molars** – the three cheek teeth at the back of the mouth
-

---



# Deciduous Teeth

- A total of 24 “baby” or “milk” teeth in the young horse
- 12 incisors and 12 premolars
- No canines or molars!



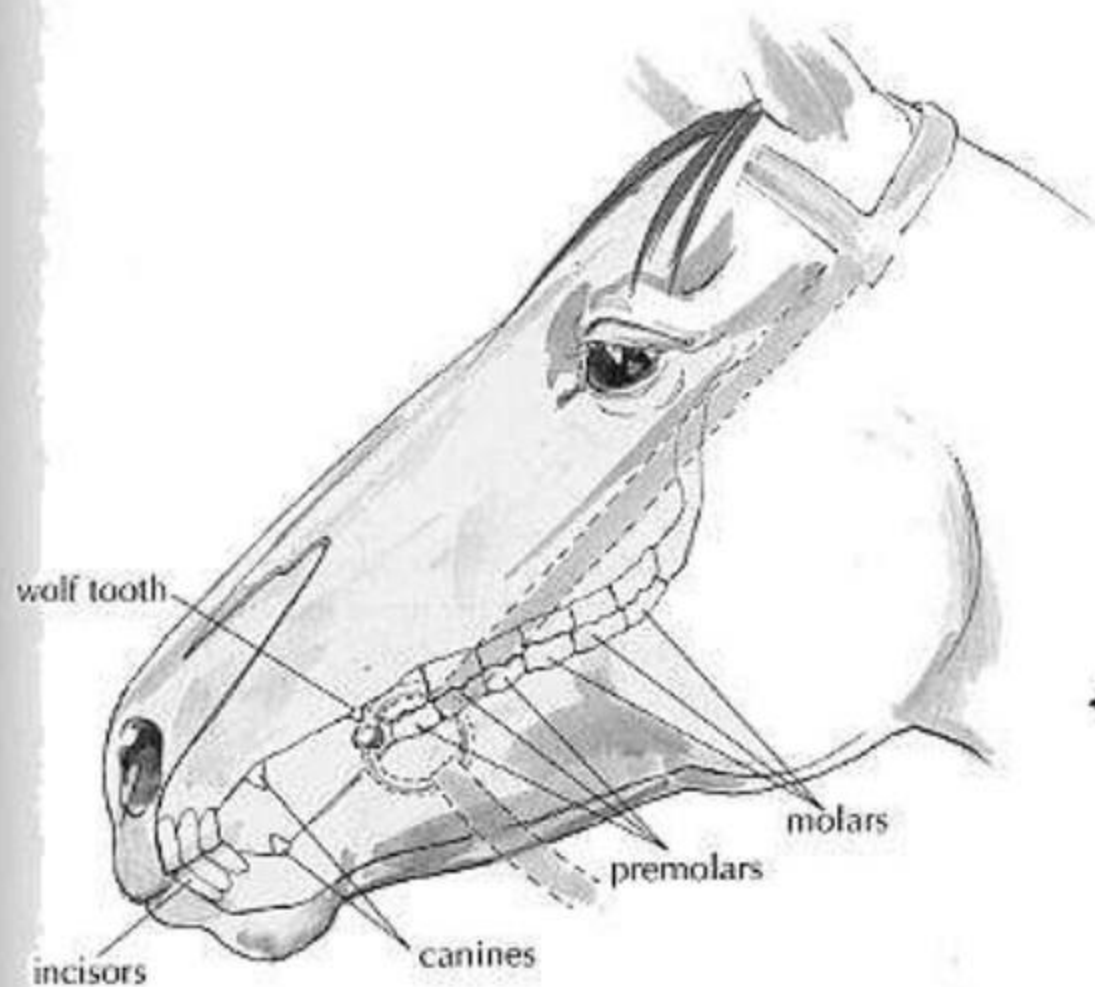


---

# Permanent Teeth

- Replace the deciduous teeth, where present
    - The deciduous tooth that precedes the permanent tooth is called a **cap**
  - From eruption to being in wear is ~6 months
  - Continue to grow, using up the reserve crown over many years
  - Adult stallion with wolf teeth has **42** teeth
-

reprinted from Horse Health Care, © 1997 Cherry Hill



◀ **MATURE MALE HORSE**

This shows the teeth of a mature male horse. Note that the canines have already emerged, all of the permanent molars and premolars are present, and that a wolf tooth is present.



Hanne Engstrom



---

# Permanent Teeth

- Six cheek teeth
    - Premolars 2, 3, and 4
    - Molars 1, 2, and 3
    - Fourth cheek tooth is the first molar
  - First premolar = **wolf tooth**
    - May be absent or very small in adult
  - Incisors:
    - Central
    - Intermediate
    - Corner
-





# Eruption Dates

	Deciduous	Permanent
1 <sup>st</sup> incisor	0 – 1 week	2 ½ years
2 <sup>nd</sup> incisor	4 – 6 week	3 ½ years
3 <sup>rd</sup> incisor	6 – 9 months	4 ½ years
*Canine		4 – 5 years
1 <sup>st</sup> Premolar (wolf tooth)		5 – 6 months

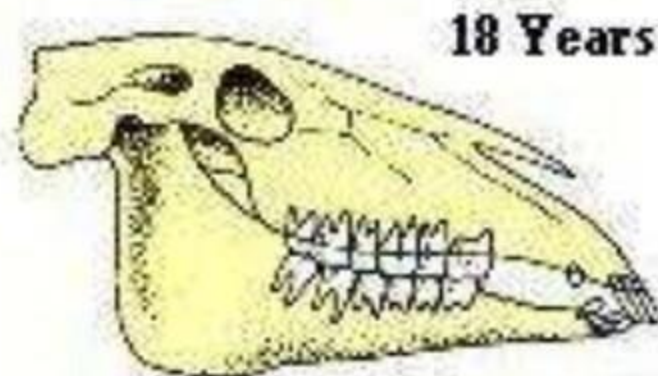
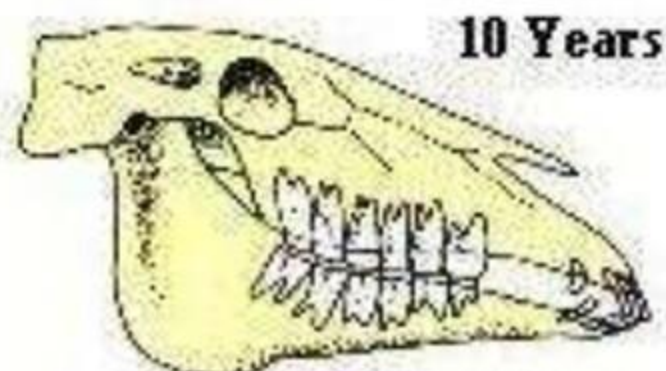
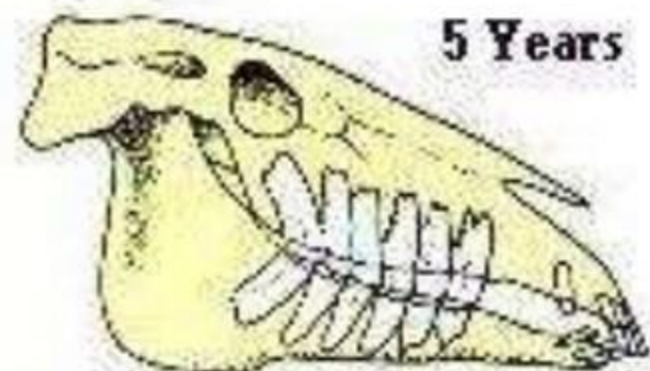


# Eruption Dates

	Deciduous	Permanent
2 <sup>nd</sup> Premolar	0 – 2 weeks	2 ½ years
3 <sup>rd</sup> Premolar	0 – 2 weeks	3 years
4 <sup>th</sup> Premolar	0 – 2 weeks	4 years
1 <sup>st</sup> Molar		9 – 12 months
2 <sup>nd</sup> Molar		2 years
3 <sup>rd</sup> Molar		3 ½ - 4 years

# Aging by teeth

- An imprecise science – after the permanent teeth have erupted and are in wear, aging by teeth is a matter of judgement!





---

# Things to consider

- Permanent vs. deciduous teeth
  - 7 and 11 year hooks
  - Points and stars. Enamel cups and dental stars
  - Galvayne's Groove
  - Incisor Angle
  - Lip tattoo. 1997 started the alphabet again at "A"
-