

Academic year 2023-24

FEMALE REPRODUCTIVE SYSTEM

Dr. Krishan Yadav

Assistant professor

Department of Veterinary Gynaecology
and Obstetrics

MJFCVAS, chomu

GENERAL TERMS AND BRIEF HISTORY

Vety. Gynaecology : study of patho-physiology of female reproduction in animals

Andrology : study of patho-physiology of male reproduction.

Vety. Obstetrics : branch of veterinary medicine which deals with (care and management of dam during pregnancy, before, and after parturition.

Theriogenology : branch of veterinary medicine concerned with reproduction, including the physiology and pathology of male and female reproductive systems of animals and the clinical practice of veterinary obstetrics, gynaecology, and andrology.

The term theriogenology is derived from the ancient greek words "therio" meaning (animal, "gen" meaning, creation/generation, and "ology" meaning study of, theriogenologists are veterinarians with advanced training in animal reproduction and obstetrics.

Reproduction: a complex process that involves many psychological and physio-chemical events in genesis of a new individual. Reproduction has 3 purposes: species existence, food and genetic improvement.

De graaf (1672) : described ovarian follicles

Johan Ham and Antonie van Leeuwenhoek (1677): described spermatozoa

Embryology of female reproductive system

- The fetal genital system consists of two undifferentiated gonads, two pair of ducts, urogenital sinus, genital tubercle and vestibular fold.
- This system develops from genital ridges which are present on the dorsal side of abdomen of fetus.
- This system can develop either into male or female embryo and this is known as embryonic bisexuality.
- In both the male and female during embryonic period, 2 pairs of genital ducts are formed that enter the cloaca, the mesonephric wolffian tubules and the paramesonephric/ mullerian ducts.

- In male, paramesonephric/ mullerian duct degenerate and mesonephric wolffian duct persists.
- In female, mesonephric/ wolffian duct degenerate and paramesonephric/ mullerian duct persists

Embryological structure	Adult Male	Adult Female
Gonads	Testis	Ovary
Mesentery	Mesorchium	Mesovarium
Gubernaculum	Ligamentum testis	Round ligament of uterus, Proper ligament of ovary
Paramesonephric duct/ Mullerian duct	-Regresses Appendix testis and uterus <u>masculus</u> (remanants)	Oviduct, Uterus, Cervix, vagina(cranial portion)

Mesonephric /Wolffian duct	Efferent ducts, Epididymis, Vas deferens, seminal vesicles	-Regresses Epoophoron, Paroophoron, Paravarian cyst, Gartner's duct (remanants)
Urogenital sinus	Bulbo-urethral glands and pelvic urethra	Caudal part of vagina and urethra
Genital tubercle	Glans Penis	Clitoris
Genital folds	Penile urethra	Vestibule
Genital swellings	Scrotum	Vulvar lips
Yolk sac	Primordial germ cells	Primordial germ cells

Female reproductive system

- Consists of ovaries, oviducts, uterus, cervix, vagina and vulva

1. OVARIES: paired, primary reproductive organs which produce female gamete and hormones. Attached to broad ligament by a fold of peritoneum (k/a mesovarium)

- The ovary consists of medulla and cortex and surrounded by surface epithelium.
- Main functions: production of oocyte; production of estrogen, progesterone, relaxin, oxytocin and inhibin hormone.

- Ovary consists of medulla (inner) and cortex(outer)
- Medulla: rich in connective tissue, blood vessels and nerves
- Cortex contains follicles, corpus haemorrhagicum, CL and atretic follicles.
- The ovary in mare is bean shaped organ which varies in size with season. During the winter, most mares have small and hard ovaries. As the light increases, there is an increase in connective tissue and small follicles and the ovary increases in size. The ovaries and follicles of the mare are the largest in the farm animal species. On the concave surface of the ovary is the ovulation fossa where the oocyte is released from the ovary. The outer layer of the ovary is the medulla (contains the blood vessels and nerves). The inner layer, cortex, contains the follicles.

Inflammation of ovary: oophoritis

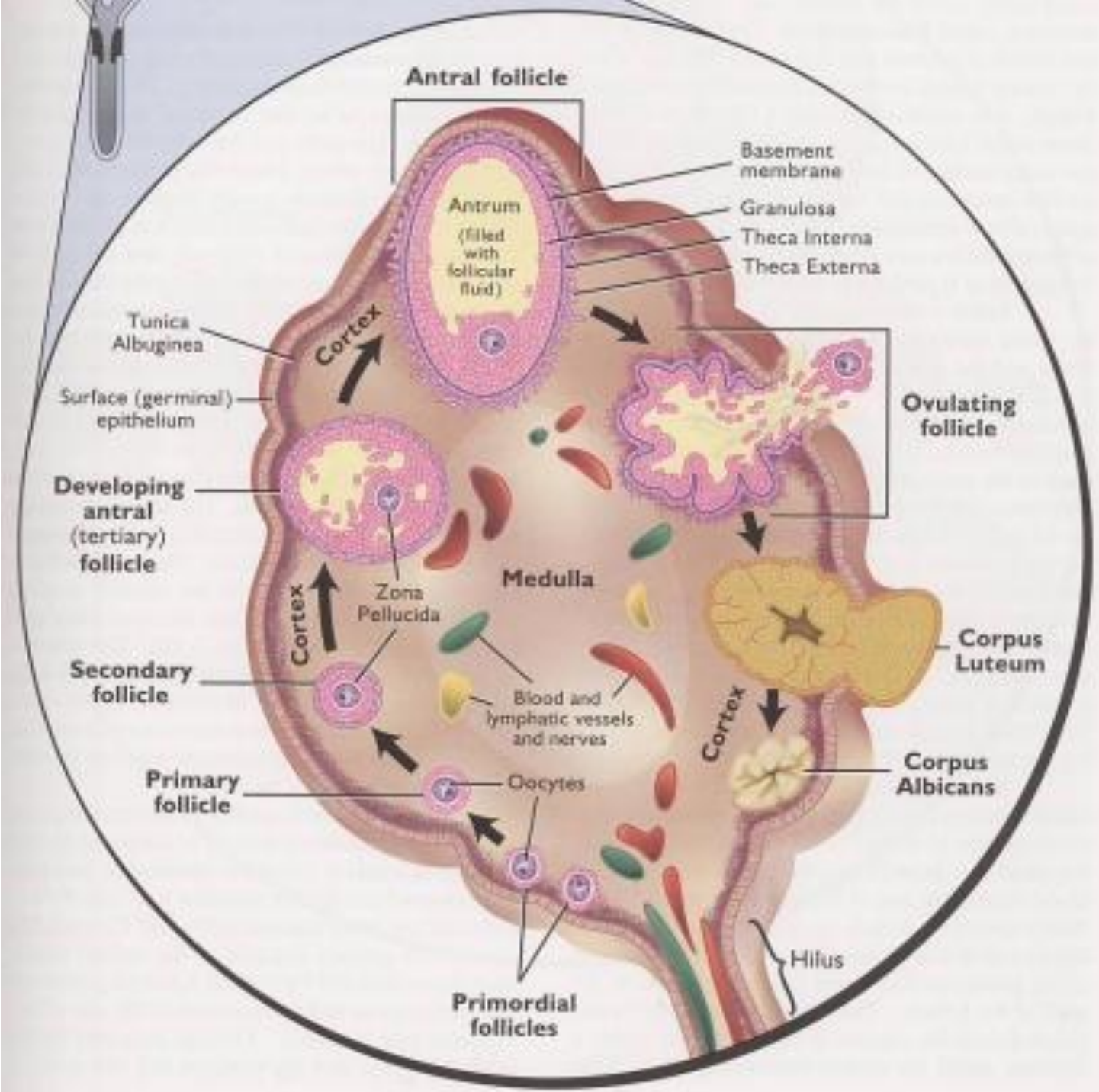
Shapes of ovaries in different species:

- Cow/buffalo: oval/almond shaped
- Mare : bean kidney shaped (ovulation fossa present) sheep/goat almond shaped
- Bitch/sow : mulberry like due to extensive follicular development
- Camel : oval
- Active ovary is slightly larger than inactive. In ruminants, right ovary is more give attached with mesovarium dorsally and laterally; ventrally attached with utero-ovarian ligament. These ligaments form a pocket like structure, known as **ovarian bursa**

- Mare is left ovulator (60%/ovulations from left ovary). Ovulation occurs at ovulation fossa.
- Bitch: ovarian bursa contains fat
- Blood supply to ovary is by utero-ovarian artery

Follicle can be:

- 1) primary: are surrounded by single layer of granulosa cells. There are about 150000 primary follicles in fetal ovaries. Group of primary follicles is known as egg nesting
- 2) secondary: are surrounded by ≥ 2 layers of granulosa cells.
- 3) tertiary follicle: when fluid filled cavity (antrum) is formed in the follicle.



4) **graftian follicle:** mature follicle containing antrum/fluid filled structure. It is surrounded by fibrous layer. It appears like a blister.

- Outer layer of graftian follicle- theca externa; inner layer of graftian follicle theca interna (secretes estrogen hormone)
- Granulosa cell at the base of ovum form cumulous cophorous on which oocyte rest.
- Oocyte's outer layer: corona radiata; oocyte's inner most layer: zona pellucida
- Contrarily in mare, the outer layer of the ovary is the medulla (contains the blood vessels an nerves). The inner layer, cortex, contains the follicles.

- **Atretic follicle:** in each cycle many follicles develop, one grows and ovulates; rest undergoes degeneration. This degenerated follicle is k/a atretic follicle
- **Liquor folliculi /follicular fluid:** contains many hormones and enzymes which help in growth and maturation of oocyte e.g. E2, p4(at ovulation), androgens, albumin, globulin, igm, FSH, LH, prolactin, cholesterol, PGE, pgf2alpha, igg (predominant; conc. Increases as follicle enlarge to preovulatory size), IgA (in amount second to igg), glucose, fructose, heparin hyaluronic acid, glycine, aspartate, threonine, alanine, na, K, zn, cu, ca, P, S, mg, cl etc. Follicular fluid helps in maturation of oocyte.

Cattle: 12-20mm
Buffalo: 10-12mm
Mare: 35-40mm.

graffian
follicles

Corpus haemorrhagicum (CH): ovulation-follicle collapse-cavity formation-bleeding in cavity-cavity filled with blood-ch. CH is freshly formed CL, brick red in colour, soft on palpation and starts projecting out of ovarian surface.

Corpus luteum (CL): CH is replaced by CL. It is rich in blood supply. Contains 2 types of cells a) **large lutein cells:** originate from granulosa cells b) **small lutein cells:** originate from theca cells. Maximum size of CL (20mm) is attained on day 15-16 of estrous cycle. After day 16, CL regress and P4 level drop simultaneously. CL is yellow coloured (yellow body), in cow and mare, whereas grey coloured in bitch and sow. CL is "nipple" like in appearance.

CL Spurium: It is CL of estrous cycle (Cyclic CL). Well projected out of surface of the ovary. In buffaloes it is invariably embaded in nature and creates problem during per rectal examination.

CL Albicans: After regression of CL a hard, scar like structure is left on the ovary k/a CL albicans. It is white coloured body (White body).

CL Verum: CL of pregnancy. Occupies (75%) area of the ovary, gets embaded in the ovarian cortex due to its increased weight. The CL of pregnancy and mature CL of estrous cycle weigh from 3-9 g or an average of 5-6.5g. Its consistency is liver" like.

CL of mare is "Cauliflower" shaped and the diameter is 3/4 to 1 inch.

- **Monotocus species:** have one ovulation and produce single offsprings e.G. Mare, cattle, buffalo
- **Polytocus species:** have multiple ovulations, many offsprings e.G. Bitch, sow.
- **Monoestrus species:** exhibit one estrous cycle which is followed by a period of long anestrous e.g. bitch
- **Polyestrous spp:** exhibit continuous regular estrous cycles through the year e.g. Cattle, buffalo. Buffalo is basically a polyestrous animal but shows summer anestrous.

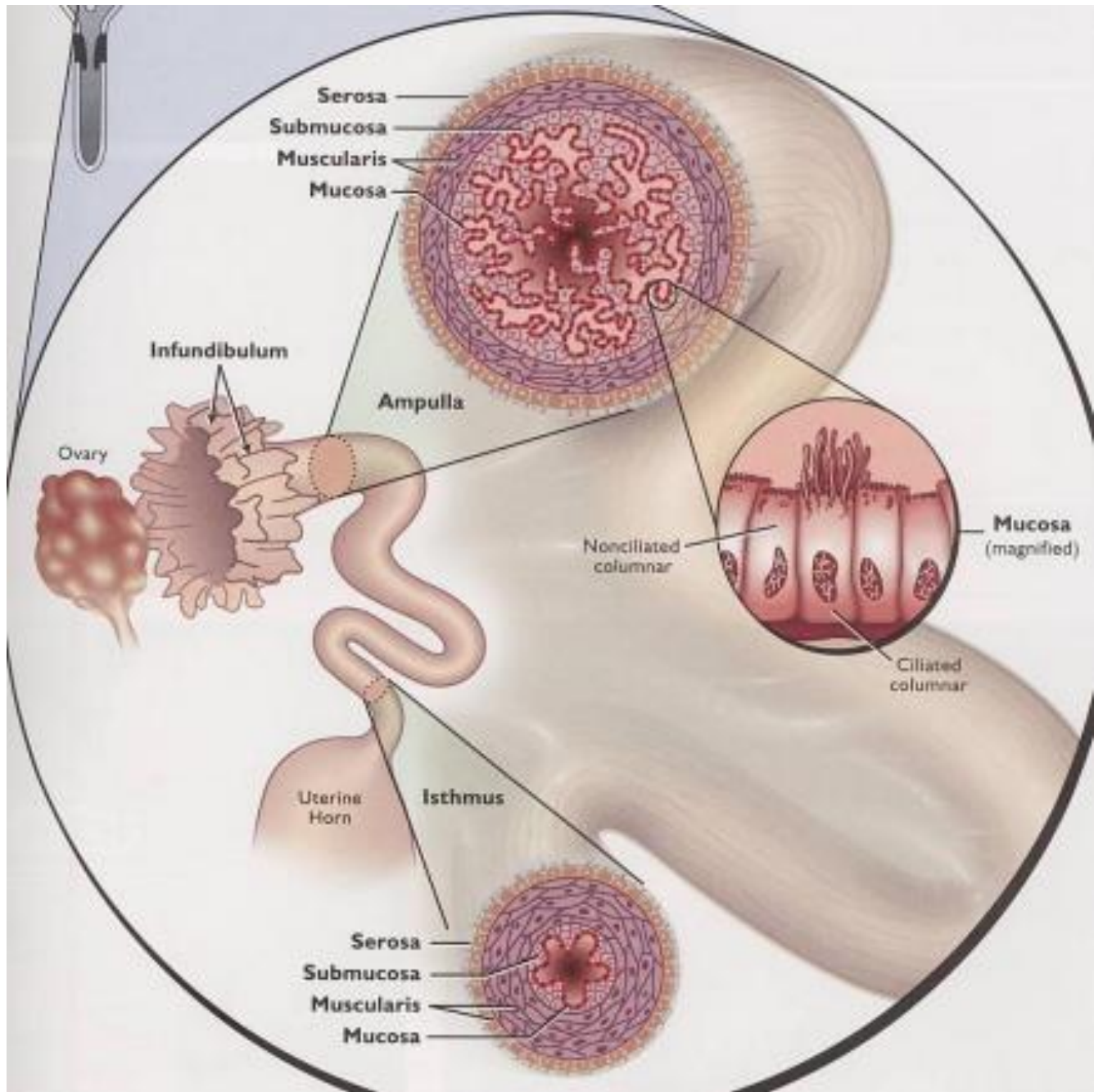
Blood supply:

- **Utero-ovarian artery**- fallopian tubes and anterior parts of uterine horns
- **Middle uterine artery:** posterior parts of uterine horns and anterior part of body of uterus
- **Caudal uterine artery:** posterior part of body of uterus and anterior part of vagina
- **Different portions of broad**

2. OVIDUCTS (Fallopian tubes/Salpinges):

paired; convoluted tubes extending from near the ovary to the tip of uterine horn. Oviducts are embedded in the bursa (derived from lateral layer of broad ligament, mesosalpinx).

Oviduct has three segments; infundibulum (towards ovarian end), ampulla (middle part) and isthmus (towards uterus). The funnel shaped opening of oviduct towards ovarian end is known as infundibulum which has fimbria for capturing the ova following ovulation.



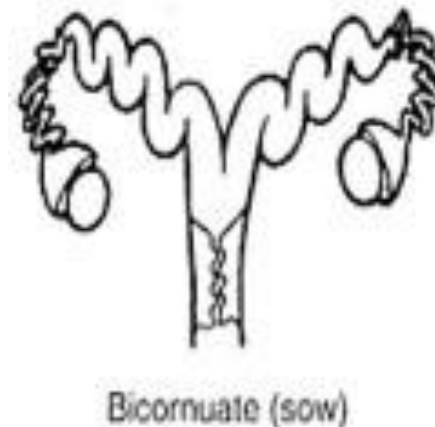
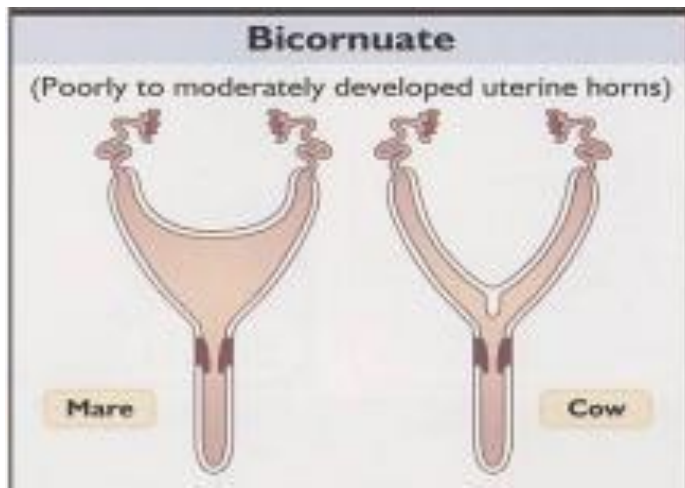
Main functions: picking up of ova following ovulation, gamete transport to site of fertilization (ampullary isthmic junction), and transport of zygote/embryo towards uterus for implantation.

Inflammation of oviduct: Salpingitis

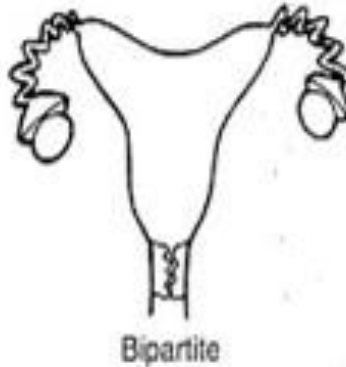UTERUS

Consists of a uterine body and two uterine horns (conua). Types of uterus:

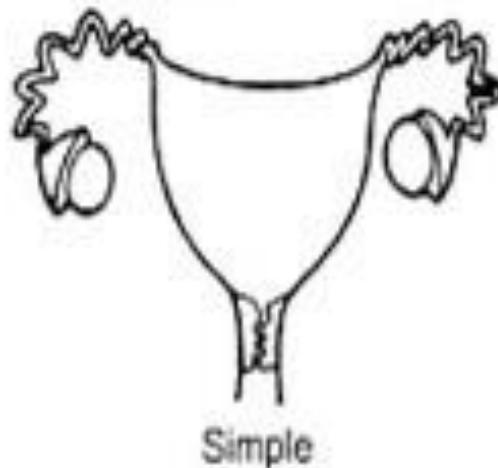
A). Bicornuate uterus (small uterine body and two long uterine horns): cow, buffalo, sow, bitch, doe and ewe. Largest uterine horns among domestic animals are seen in sow.



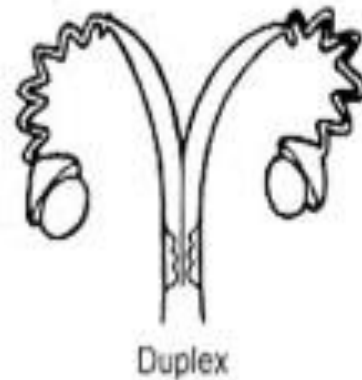
B). Bipartite uterus (prominent body and shorter horns: cruciform or T-shaped): **Man**



C). **Simple/Simplex uterus:** uterus has pear shaped body with fo uterine horn, e.g. Human beings and other primates



uterine horns each with a separate cervical canal which opens into vagina e.g Rat, Guinea Pig and other rodent



Ruminant uterus has mushroom like non-glandular projections known as Caruncles. Caruncles are arranged in two dorsal and two ventral rows on the endometrium.

No. of caruncles in different species: Cattle 75-120, Buffalo 60-90 and Sheep 80-90 (In some books 88-96)

Both the horns are joined by dorsal and ventral intercornual ligaments.

Main functions of uterus:

a) Gamete transport and capacitation: Due to contractions of smooth muscles and uterine mucus the spermatozoa are transported through uterus to oviduct and the uterine environment helps in capacitation of sperms

b). Implantation and Gestation: After few days, zygote gets attached into uterus and draws nutrition from uterus. As size of zygote followed by embryo and fetus increases uterus enlarges to accommodate the developing fetus. Before implantation the embryo takes nutrition from uterine glands of uterus and the secretion of these glands is known as Uterine milk/Histotroph

c) **Luteolytic functions:** Synthesis of PGF_{2a} which is responsible for luteolysis. PGF_{2a} is derivative of unsaturated hydroxy acids like Arachidonic acid and linolenic acid.

d) **Parturition:** After completion of gestation myometrial contractions help in expulsion of fetus

e) Serve as site of semen deposition during natural mating in sow and mare.

Inflammation of different layers of uterus:

Endometrium- endometritis,

Myometrium (middle layer)-Myometritis,

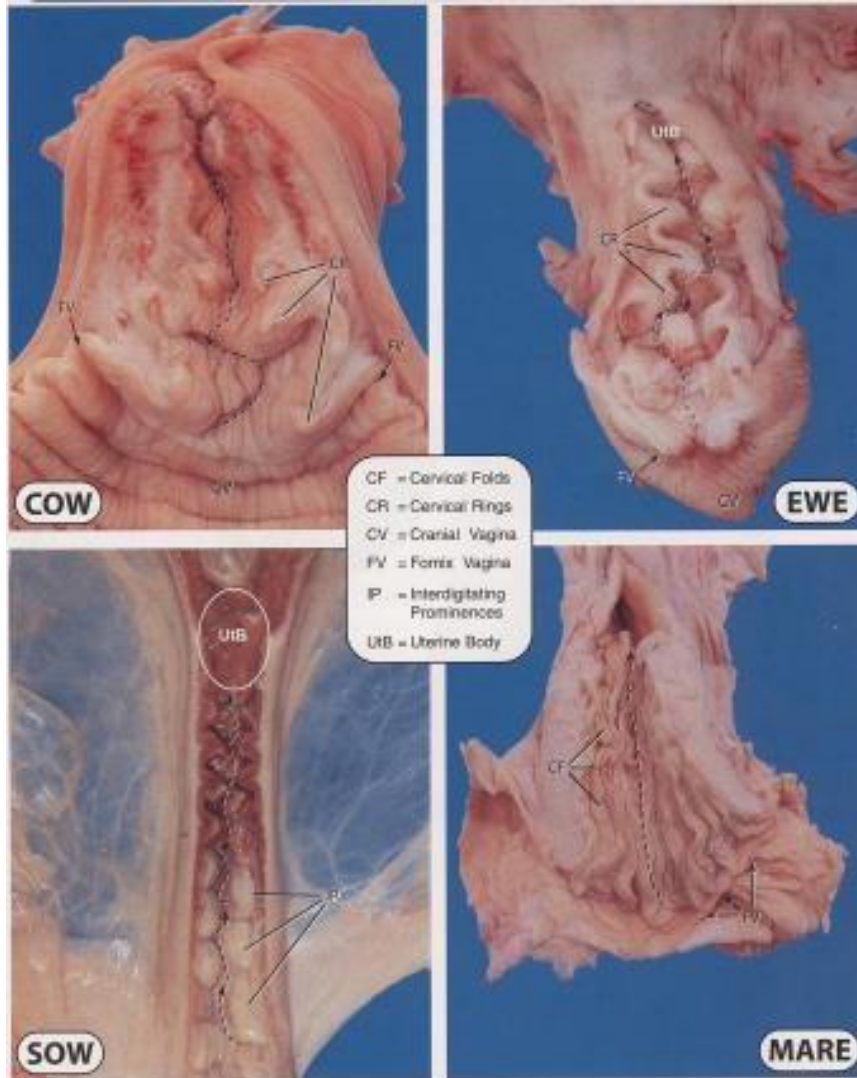
Perimetrium (Outer layer/serosal layer- Perimetritis,
Uterus (all the three layers)-Metritis and
Broad ligaments-Parametritis.

CERVIX

A tubular structure with constricted lumen which act as door way to the uterus.

Cervical canal in cow, buffalo, doe and ewe has annular rings (interlocking ridges) where as in sow the canal is funnel shaped and cork screw like)

The annular rings are 3-3 in cattle and 1-3 (mostly only 2) in number in buffalo.



The cervix of the cow and ewe have distinct, well developed protrusions called cervical rings (CR). The sow has interdigitating prominences (IP). The mare has no cervical rings but has many longitudinal cervical folds (CF) that are continuous with the endometrial folds of the uterus. Arrows indicate the pathway of the cervical canal from the cranial vagina (CV) toward the uterus.

The cervical canal in mare is more open and having conspicuous folds in mucosa and the folds projecting into vagina than other farm species.

Main functions: prevents entry of infection in uterus; transport and store spermatozoa

In bitch, cervix is poorly defined

Sow: Cork Screw like penis of boar gets interlocked in cork screw like cervix

Cervix opens at estrus and peri-parturient, otherwise remains closed.

Cervix projects into vagina like a knob and has a central opening called as external os Anteriorly, it opens into body of uterus called as internal os.

Inflammation of cervix: Cervicitis

VAGINA

The vagina is tubular in shape and highly musculo-membraneous located dorsal to urinary bladder in pelvic cavity.

The mucosal layer of the vagina is composed of stratified squamous epithelial cells. These epithelial cells become cornified under the influence of estrogen.

External urethral orifice is the landmark junction of vagina and vulva i.e. vagina is extended from the cervix to the external urethral orifice.

At floor of vagina two ducts, Canals of Gartner (remanant of wolffian/mesonephric ducts) which open on either side of external urethral opening

Main functions: it serves as copulatory organ of females, site of semen (deposition during natural mating in cow, buffalo, ewe and doe and acts as a part of birth canal and also serves as excretory duct for the secretions of cervix, endometrium and oviduct.

Inflammation of vagina: **Vaginitis**

Vulva

Also called as external genitalia and consist of vestibule, clitoris and vulvar lips. It acts as an external opening to reproductive tract.

The vestibule is common to both reproductive and urinary system and contains hymen. Clitoris is located in the ventral commissure and it is more prominent in mare and sow .

The vestibular glands or Bartholian glands (two almond shaped) located under the mucus membrane in the posterior part of vestibule, are active during estrus and secrete lubricating mucus.

Vestibular glands are homologous to the bulbourethral /Cowper's glands.

The luminal space around the external os of cervix is known as Fornix vagina. Fornix vagina is absent in sow.

Hymen (transverse ridge) is located at the junction of vagina and vestibule which is well defined in the ewe and mare but ill-defined in cow, buffalo and sow.

Labia consist of labia minora (homologous to prepuce in male) which is not prominent in farm animals and labia majora (homologous to scrotum in male).

Clitoris is homologous to glans penis in the male.

Upper commissure is acute and separated from anus by a short distance whereas lower commissure is elongated and bears a tuft of hairs,



Thank you