

**MJF COLLEGE OF VETERINARY AND ANIMAL SCIENCE,
CHOMU, JAIPUR**



DEPARTMENT OF VETERINARY PATHOLOGY

Musculo-skeleton System

NORMAL BONE FORMATION

- **Bone cells**
- Bone has three types of cells. They are as follows
 - **Osteocytes** are the ordinary bone cells that are found in the lacunae. These are old cells that cannot divide.
 - **Osteoblasts** are bone producing mesodermal cells and line the deep layer of periosteum, the endosteum and the Haversian canals. These cells like fibroblasts have great power of proliferation and produce alkaline phosphatase. Osteoblasts secrete precursors of collagen and mucopolysaccharides. The latter act as the cement substance and in this is embedded collagen. These form the matrix of the bone called osteoid.
 - **Osteoclasts** are the phagocytes of bone and are multinucleated. Foreign body giant cells can be formed from them. These are under the control of parathyroid and under its influence remove bone.

Various factors which govern bone formation

- ***Proteins***: Sufficient amount of protein must be fed for the formation of the ground substance- osteiod.
- ***Minerals***: sufficient amount of calcium and phosphorus must be supplied in the food in correct proportion and the intestinal tract must be healthy and of correct pH for their absorption. Normally, the Ca : P ratio in food should be 2:1.
- ***Vitamins***: Vitamins A, D and C control bone formation.
 - Vitamin **A** deficiency produces inanition and growth rate is retarded. It is concerned with the metabolism of endothelial cells and so is required for the proliferation of endothelial cells of the capillaries, for their transformation into osteoblasts and for the erosion and removal of the calcified cartilage.
 - Vitamin **D** controls absorption and utilization of calcium and phosphorus.
 - Vitamin **C** controls the formation of osteoblasts and so controls deposition of osteoid.
- ***Alkaline phosphatase***: The alkaline phosphatase found in bone is formed by the osteoblasts. This enzyme splits the organic phosphate compounds liberating excess of phosphate which upsets the local calcium phosphate balance leading to the precipitation of calcium salts. It is in this manner that mineralization of the osteoid (the organic matrix of the bone) takes place.

Abrachia	Absence of anterior limbs.
Apodia	Absence of posterior limbs.
Micromelia	All parts of limbs are present but are of smaller size.
Perodactyly	Absence of all toes in a limb.
Brachydactylism	Abnormal shortening of toes.
Polydactylism	Presence of more number of digits; seen in horse and pig.
Syndactylism	Fusion of toes seen in cattle and pigs.
Prognathism	Having a long jaw; pig-mouth condition in horse
Brachygnathism	Having a short jaw; parror-mouth in horse.
Kyphosis	Abnormal dorsal curvature with prominence of spine (hump back) is called kyphosis. It is rare in animals.
Lordosis	It is the curvature of the spine with a ventral convexity due to heavy loads or heavy abdominal organs; terminal parts of the thoracic spine and the lumbar spine are involved. The spinous processes rub against each other and so periostic osteophytes develop.
Scoliosis	Abnormal lateral curvature of the spinal column is called scoliosis. It may be congenital and sometimes inherited. It may be due to disease of bones like achondroplasia, osteodystrophy.
Torticollis (Wry neck)	This is twisting of the neck with an unnatural position of the head.
Osteodystrophy	<p>It denotes disturbance in the growth of bone. Osteodystrophies may be acquired or congenital. It may be due to</p> <ul style="list-style-type: none"> • Lack of minerals and vitamins (Rickets and osteomalacia etc.) • Excessive hormones- gigantism acromegaly, osteoporosis. • Unknown causes.

Rickets

- **Definition**

- This is a condition seen in young growing animals in which there is a failure of adequate calcification of bones.
- Similar condition in adult mature animals in which growth of bones has stopped is known as osteomalacia – literally meaning softening of bones.

- **Etiology**

- Rickets is a deficiency disease caused by deficiency of calcium phosphorus or Vitamin D. The deficiency of these may arise in several ways.

Deficiency of calcium

- ***Deficiency of calcium in the diet:*** Inadequate calcium in the diet may not occur in animals.
- ***Increased requirements in growing animals:*** if adequate quantities are not allowed in the ration deficiency may arise in growing animals in which the needs for calcium and phosphorus are great.
- ***Failure of absorption of calcium:*** Calcium is mostly absorbed as CaH PO_4 and for this the medium must be acidic. If the intestinal contents are excessively alkaline, calcium cannot be easily absorbed.
- ***Improper balance of calcium and phosphorus:*** Excess of phosphorus in the ration (feeding too much of bran etc), may combine with calcium and form a relatively insoluble $\text{Ca}_3 (\text{PO}_4)$ which is excreted in feces.
- ***Formation of insoluble complexes:*** Oxalates and phytates present in some green leaves and grains respectively may form insoluble compounds in monogastric animals and are lost in the feces. Excess of oxalic acid in leaves and excess of lactic, tartaric, and malic acids in silage bind calcium in large quantities. If the feed is too coarse, then greater amounts of hippuric acid is formed from cellulose. If food is too rich in protein, acid breakdown products of proteins bind calcium. When sulphur is fed to chicks as a coccidiostat, it combines with calcium to form insoluble compounds which are lost in the feces.

- ***Poor utilization of calcium*** may occur leading to calcium deficiency. Too rich or poor fat reduce the utilization of calcium. Reduced body movement may also reduce the utilization of calcium.
- ***Steatorrhoea***: In dogs fatty acids from fats that are not assimilated may combine with calcium, forming calcium soaps which are lost in the feces. This is common in man in Coeliac disease. Since Vitamin D absorption is conditioned by absorption of fat, in steatorrhoea, Vitamin D also is not absorbed and this still further affects the absorption of calcium since vitamin D is not only necessary for calcium absorption but it also increases calcium absorption by the intestinal mucosa.
- ***Renal disease***: In nephritis, phosphorus is not excreted as it should be and so accumulates in the blood and body. The excess phosphate ions are excreted through the intestinal tract, where they combine with calcium to form insoluble compound which is lost in the feces.

- **Deficiency of phosphorus**
- ***Inadequate amounts of phosphorus in diet:*** In certain parts of the world soil is deficient in phosphorus and so animals maintained solely on the plants from such soils develop phosphorus deficiency which is clinically manifested as osteophagia (pica).
- ***Increased requirements:*** In growing animals, if adequate quantity of phosphorus is not allowed in the ration deficiency will result.
- ***Formation of insoluble complexes:*** Excess of Calcium, iron and aluminum form insoluble phosphorus compounds and so phosphorus deficiency results.
- ***Change of reaction of intestinal contents:*** An acid medium is required for the absorption of CaH PO_4 . But if the reaction changes, absorption cannot occur.
- ***Steatorrhoea:*** Vitamin D is necessary for the absorption of phosphorus also. In steatorrhoea vitamin D is not absorbed and so is not available to the body and so phosphorus is also not absorbed.

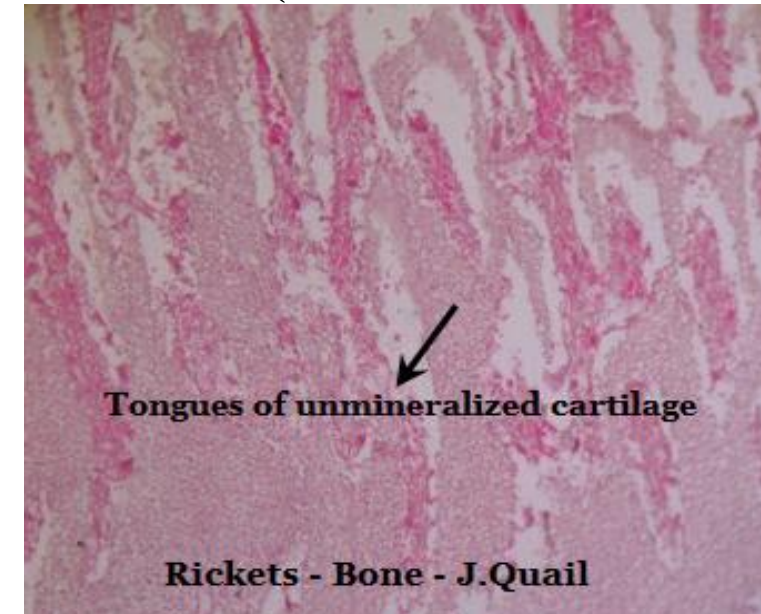
- **Deficiency of vitamin D**
- Insufficiency of vitamins D may occur in young animals due to the following causes
 - ***Deficiency of sunlight:*** Since vitamin D can be formed in the skin by the action of ultraviolet rays on ergosterol, deficiency of sunlight may cause deficiency of vitamin D. Smoke and smog in industrial places filter the ultraviolet rays and so rickets may supervene.
 - ***Diseases of liver:*** If sufficient bile is not secreted, absorption of vitamin D may be interfered with.
 - ***Steatorrhoea:*** Vitamin D is not absorbed in the absence of fat.

- **Pathogenesis**

- The essential defects in rickets are
 - The cartilage cells are resistant to degeneration and are not calcified.
 - The blood vessels fail to invade and corrode the cartilage.
 - On the persistent and growing cartilage, there is overgrowth of the osteoid.
 - The osteoid is not calcified.
 - In the osteochondral zone, fibrous tissue proliferates.

- **Clinical signs**

- Stunted growth - shortening of bones results in rachitic dwarfism.
- Kyphosis and scoliosis
- “pot-bellied” appearance of the abdomen
- On pressure and due to weight the bones bend - bowing of the limbs (“bow legs”)
- Bending of knee and fetlocks
- Enlargement of ends of bones and joints
- Over-extension of pasterns with overgrowth of hooves
- Cranium is more dome shaped and the fontanelles are wide
- Jaws cannot be closed
- Teeth may be poorly formed and irregular
- “Rickety-rosary” (enlarged chondrocostal joints appearing as a string of beads)
- Deformity of the pelvic bones (which later may cause material dystocia)
- Crooked sternum in birds.



- **Clinical pathology**

- There may be decrease in serum calcium and phosphorus and increase in alkaline phosphatase.

- **Gross pathology**

- The epiphysis cartilages are abnormal wider and soft and so can easily be cut. The osteochondral zone is softer than normal.

- **Histopathology**

- The epiphyseal cartilage cells persist and grow and so the zone of cartilage is wider and longer. Therefore chondrocostal and osteochondral junction are widened and enlarged.

- In the osteochondral junction irregular tongues of surviving and resistant cartilage cells appear to be arranged in a disorderly and crooked manner.

- Osteoid which is pink staining is abundant while the blue staining bony trabeculae are few and widely separated.

- Overgrowth of fibrous tissue occurs at the osteochondral zone and in the marrow. There is therefore reduction of myeloid cells.

- **Diagnosis**

- X ray shows enlargement of epiphyseal plate, enlargement of epiphyseal line and bending bones.

- **Sequelae**

- Restitution of the deficiencies corrects the disorder. But deformities persist e.g. “bowlegs”

osteomalacia

- **Synonym**

- This condition is otherwise known as adult rickets.

- **Occurrence**

- It occurs in animals in which endochondral ossification has ceased.

- Osteomalacia may be seen in pregnancy when maternal calcium is drained to the fetus and in high yielding cows in which large amounts of calcium are excreted through the milk.

- **Etiology**

- The causes for osteomalacia are similar to those of rickets.

- **Pathogenesis**

- Because of either excessive demands of the body for minerals or deficient in the dietary intake of the minerals to meet the demands of the mineral requirement by the body bone resorption occurs.

- **Clinical signs**

- Kyphosis and lordosis are frequently seen together with narrowed pelvis.
- Because of lack of mineralization the skeleton becomes soft and fragile and so fractures and deformities occur.
- The articular heads of some of the bones may sometimes separate.

- **Histopathology**

- Presence of excess of osteoid
- Failure of calcification of matrix (atrophy of the bone substance) and.
- The medullary cavity is enlarged.
- Compact bone becomes spongy in extreme cases and ultimately a membranous sac covered over by the periosteum containing traces of bone is left.
- Active resorption of bone by osteoclasts
- Reduction in size and number of the trabeculae of spongiosa

Osteodystrophic fibrosa

- **Synonym**

- In the horses, osteodystrophia fibrosa is known as “Bran disease” or Big head” or “Miller’s disease”

- **Occurrence**

- Frequently occurs in animals.
- It is common among horses maintained by millers.

- **Etiology**

- Feeding of animals with bran alone.
- If the calcium phosphorus ratio in feed is reversed or becomes 1:3 or wider, osteodystrophia fibrosa results.

- **Pathogenesis**

- Since bran is a cheap by-product in the milling of wheat, horses of the millers are maintained exclusively on bran which has high phosphorus content.
- This phosphorus combines with calcium of the food and forms insoluble Ca_3PO_4 in the intestine and is excreted in the feces.
- Therefore sufficient amount of calcium and phosphorus are not available to the body and so hypocalcemia results.
- This in turn causes osteomalacia.
- Hypocalcemia stimulates the parathyroid which becomes hypertrophic producing excess of parathormone.
- This hormone acting on the bone (through the osteoclasts) decalcifies it producing osteomalacia.
- The bones become soft as calcium is withdrawn from them.
- So as to strengthen the bones, fibrous tissue proliferation occurs.
- Since soft bones bend and twist, irritation is produced and this causes inflammation to occur which ultimately is responsible for fibrosis.
- This fibrosis is most apparent under the periosteum hence the bone appears larger than normal.
- The bone marrow may also be replaced by the fibrous tissue.

- **Clinical signs**

- Initially

- abnormal gait - stiffness
- shifting lameness

- These symptoms are later followed by

- Anorexia
- Anemia (the anemia is myelophthisic in origin – due to swelling of the jaws)
- Cachexia.
- Dyspnoea due to narrowing of the nasal passages
- Difficulty in mastication
- Loosening and loss of teeth
- Fractures (common in occurrence)

- **Gross pathology**

- All bones are not equally affected. The bones that are most active are affected. This affection is first noticed in the facial bones.
- The facial bones of the horse appear swollen and hence the name “Big Head”.

- **Histopathology**

- **Microscopically,**

- large masses of fibrous tissue are seen in which are found remnants of bony trabeculae.
- sometimes the fibrous tissue may be of such proportion as to resemble a fibroma

OSTEITS FIBROSA CYSTICA

- **Synonym**
- Von Recklinghausen's disease
- **Definition**
- This condition is a form of osteodystrophia fibrosa characterized by decalcification of bone, substitution by fibrous tissue and formation of cysts.
- **Etiology**
- This condition is caused by hyperparathyroidism.
- **Hyperparathyroidism** may be:
 - **Primary:** As in a tumor of the Parathyroids.
 - **Secondary**
 - Dietary calcium insufficiency
 - Dietary phosphorus insufficiency
 - Chronic renal disease.

- **Pathogenesis**

- The parathyroids are sensitive to blood calcium level.
- Any decrease in blood calcium stimulates the parathyroids and hyperplasia occurs with increased production of parathyroid hormone.
- Normally glomeruli filter phosphates some of which are reabsorbed by the tubules. But in renal disease the phosphate excretion is much reduced and so the phosphate level of the blood raises – hyperphosphatemia. To compensate for the rise and to keep the Ca: P ratio constant, calcium is withdrawn from the bones.
- Besides the retained phosphate is excreted through the bowel where it combines with calcium and forms an insoluble compound and so is lost from the body resulting in hypocalcemia. Which stimulates parathyroid liberating excess of hormone and this withdraws calcium from the bone through the mediation of osteoclasts to maintain normal blood calcium level.
- The function of parathyroids is therefore homeostasis to maintain the optimum Ca: P level in the blood.
- The activity of parathyroids is increased two folds to facilitate excretion of phosphorus in the urine.
- When calcium is removed from the bones, they become soft and weak and so to strengthen them, there is fibrous tissue proliferation. This change though found in all the bones, it is more prominent in the bones of the head.

- **Gross pathology**

- In the dog, the lower jaw becomes so soft that it is as pliable as rubber. “Rubber –jaw syndrome”.
- Since the newly formed connective tissue is poorly supplied with blood. Degeneration, softening and cyst formation occur – hence the name osteitis fibrosa cystica .

- **Histopathology**

- **Microscopically**

- Osteoid and fibrous tissues are more.
- Attempts to form a new bone in some places is evident by the presence of osteoblastic activity.
- In other places, osteoclasts are seen nibbling away spicules of bone.
- Cysts of varying sizes and hemorrhages are seen.

OSTEOPOROSIS

Definition

- In this disorder, there is reduction in the bony matrix. But what is present is fully mineralized (whereas in rickets and osteomalacia tissue matrix is formed but inadequately mineralized).

Etiology

- **Senility:** Due to decreased osteoblastic activity or decreased sex hormones.
- Local pressure on bones may cause atrophy: for example tumors, *Coenurus cerebralis*, hydatid cysts and pulsating arterial aneurysms in contact with vertebra.
- Lack of protein as in loss of protein (renal disorder), lack of production as in liver disease or defective absorption due to intestinal disorders. Protein is essential for the formation of osteoid, without which bone cannot be formed.
- Deficiency of vitamin A leads to decreased production of osteoblasts
- Deficiency of Vitamin C: Osteoblasts and osteoid are not formed.
- Disuse: for proper healthy condition of the bone to be maintained exercise is necessary. If a part is immobilized for a long time, bone of that part becomes thinner and porous due to increased activity of the osteoclasts and inactivity of osteoblast (due to lack of normal stimulus of stresses and strains).

- Loss of nerve supply to the part results in paralysis and so the part cannot be moved and osteoporosis will result.
- Deficiency of trace elements : - copper deficiency in dogs; manganese deficiency in pigs and zinc deficiency on fowls.
- Hyperthyroidism: Osteoclastic activity is probably increased.
- Hyperparathyroidism: Increased resorption of bone occurs.
- Cushing's syndrome: Excess of glucocorticoids probably suppresses the osteoblastic activity. Bodies of vertebrae are severally affected.
- Lack of either androgens or estrogens: In human pathology, osteoporosis is frequently observed after menopause. The sex hormones appear to have some, influence over the osteoblastic activity.
- Poisons – For example lead poisoning in sheep and goats causes osteoporosis.

Pathogenesis

- In this condition, destructive processes exceed the productive in the remodeling of bone.

Clinical pathology

- The blood levels of calcium and phosphorus are normal.

Gross pathology

- The bones appear lighter and thinner – atrophied.
- The cortex is thinner but the marrow cavity is wider.
- The bones become porous, brittle and so are prone to fractures.

Histopathology

- The bony trabecula is thinner with decreased number of osteoblasts.
- Osteoclastic activity denotes destruction of bone.

Diagnosis

- Osteoporosis can be diagnosed by **Izuka's** test.

PULMONARY OSTEOARTHROPATHY

- **Synonym**
- This condition is known as **Marie's disease in humans**
- **Occurrence**
- This is found in all animals but with greater incidence in dogs.
- **Etiology**
- This disease is noticed in the following conditions:
 - Chronic disease of heart and lungs – congenital heart disease, **bronchiogenic carcinoma** bronchiectasis, emphysema, chronic tuberculosis and neoplastic condition of the lungs
 - When there is interference in the vascular supply to the extremities.
 - Passive congestion of the affected parts.
 - *Spirocerca lupi* infection.
 - *Dirofilaria* infection
- It is surmised that anoxia, probably with some obscure toxins is the causative factor.
- **The skeletal changes are the result of reflex vasomotor disturbances in limbs secondary to circulatory disturbances in the lungs.**

Gross pathology

- There is formation of new bone mostly under the periosteum of bones of limbs, which is therefore pushed out (**Periosteal hyperostosis**).
- As the osteophytic (Osteophyte means a bony excrescence) formation is not even, the bony surface is rough.
- The articular surfaces are free.
- Joints may be swollen due to **periarticular proliferation**.
- In the **lung**, foci of **new bone formation** are seen.

OSTEITIS AND OSTEOMYELITIS

- Inflammation of the bone --- **Osteitis**
- Inflammation of periosteum ----- **Periostitis.**
- Inflammation of bone marrow -----**Osteomyelitis.**
- Inflammation of vertebrae ----- **Spondylitis .**
- Osteitis and osteomyelitis may be acute or chronic.

Acute purulent osteomyelitis

- ***Occurrence***

- This condition is not so frequent in animals as in man.

- ***Etiology***

- Acute purulent osteomyelitis is always caused by bacteria which gain entry into the bone in the following ways.
 - **Direct**
 - Through compound fractures
 - Gunshot and other wounds
 - **By lymph vessels in draining neighboring purulent areas such as:**
 - Purulent arthritis
 - Purulent periostitis
 - Gathered –nail wound
 - Suppurative otitis media
 - **By blood stream:** From a suppurative lesion elsewhere and in pyemia.
- The organisms that cause it are pyogenic bacteria, *Spherophorus necrophorus*, *Erysipelothrix rhusiopathiae*, *Salmonella* and *Cryptococcus neoformans*.

Acute periostitis

- Acute periostitis may be non-suppurative and is usually caused by trauma (concussion).
- It is seen in horses as “ sore shins ” (due to working on hard roads).

• *Gross pathology*

- The periosteum shows hyperemia with purulent exudates accumulating between the cortex and periosteum.
- The exudates may separate the periosteum from the bone and necrosis of the cortex results.
- Periosteum may be ruptured, liberating the pus into the nearby tissue.
- Since periosteum is in continuity with the endosteum and medulla, pus may pass on to these structures.
- Then, necrosis of the bone occurs due to separation of both periosteum, and endosteum on which the nutrition of the bone depends.

Suppurative osteomyelitis

- In suppurative osteomyelitis pus is found in the medullary cavity and it may burst through the cortex. But more often, such drainage is difficult and the condition progresses to chronic stage.
- In the young growing animals abscesses are found at the chondrocostal joints and in the epiphyseal plates.
- The necrosed bone is separated from the healthy bone by the action of osteoclasts and a sequestrum is formed. Osteoblasts nearby are active and produce new bone which forms a case as it were around the sequestrum and this is known as involucrum. Pus is discharged to the outside from the sequestrum through small openings in the involucrum called cloacae .
- *Sequelae*
 - Resolution and healing with timely treatment.
 - Pathological fracture due to extensive destruction of the bone.
 - Suppurative arthritis may occur due to extension of infection to the neighbouring joint; metastatic abscesses.
 - If suppurative osteomyelitis is extensive and present for a long time amyloid degeneration may occur.
 - Chronic osteomyelitis
- Death due to pyemia and septicemia.

Chronic osteomyelitis

- ***Etiology***

- It may be a sequel to osteomyelitis.
- Repeated injury or concussion especially in horses
- Bacteria of low virulence – *Actinomyces*, *Brucella*, *Mycobacterium tuberculosis*, *Salmonellosis*
- Fungi – Coccidioidomycosis.

- ***Gross pathology***

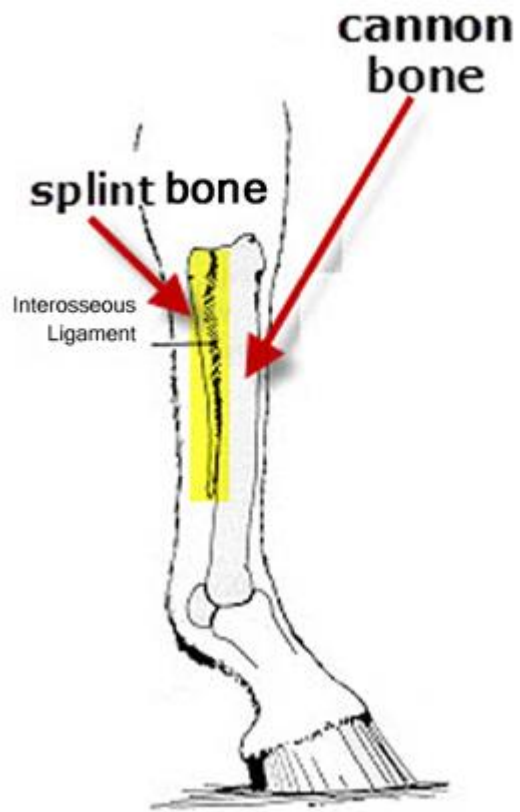
- In the case of chronic trauma and concussion, exostosis will occur.
- Exostosis is the formation of granulation tissue of the bone, just as fibrosis occurs in chronic inflammation of soft tissues
- So in the bone, chronic inflammation results in the formation of new bone. This is essentially a result of chronic ossifying periostitis.
 - **In the horse special names are given to exostoses occurring in certain locations.**

1. Ring bone: This is the exostosis found on the 1st or 2nd phalanx. This is a painful condition causing lameness.

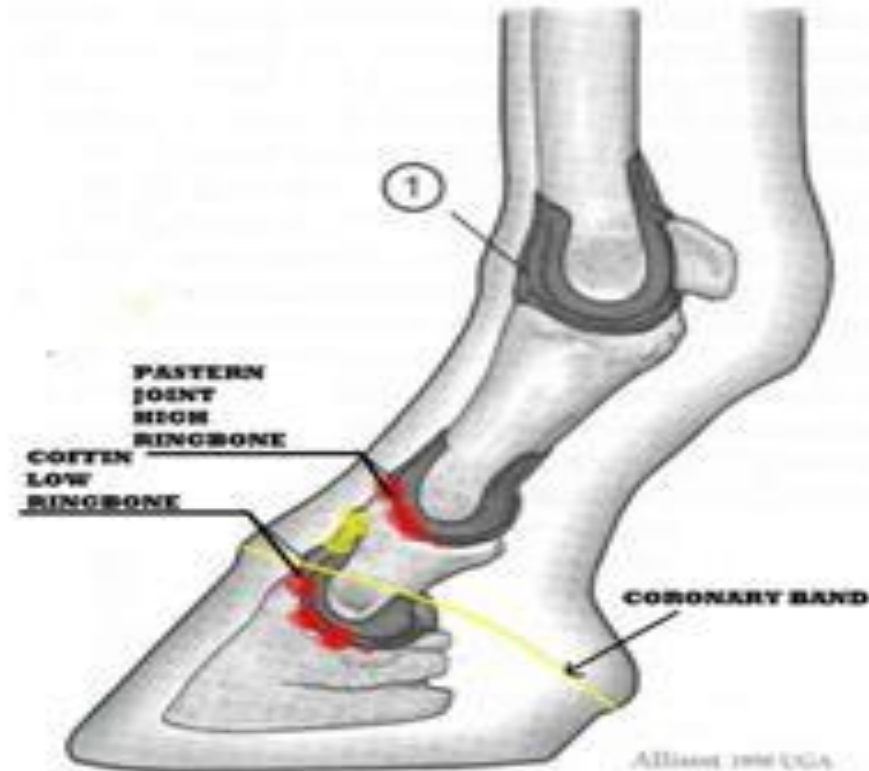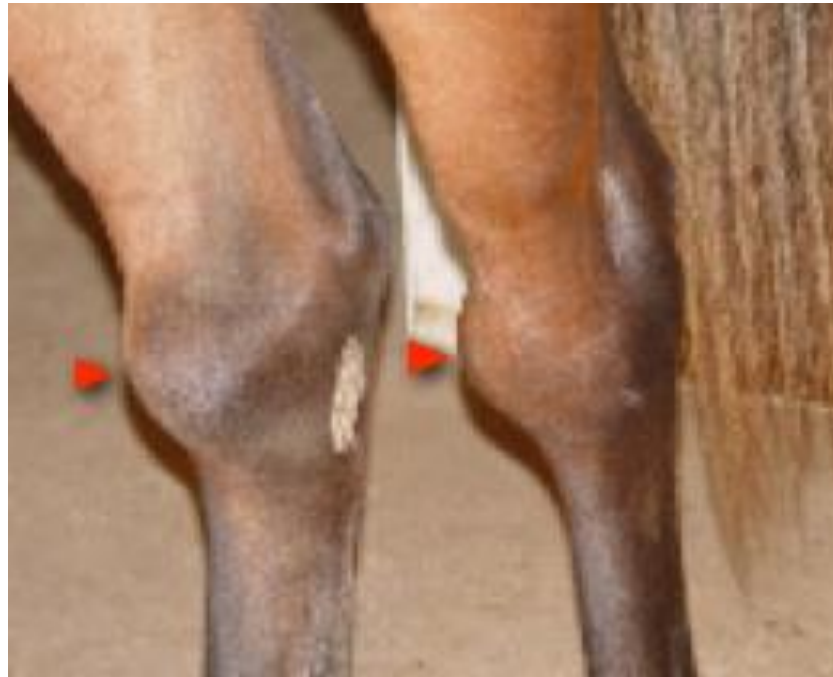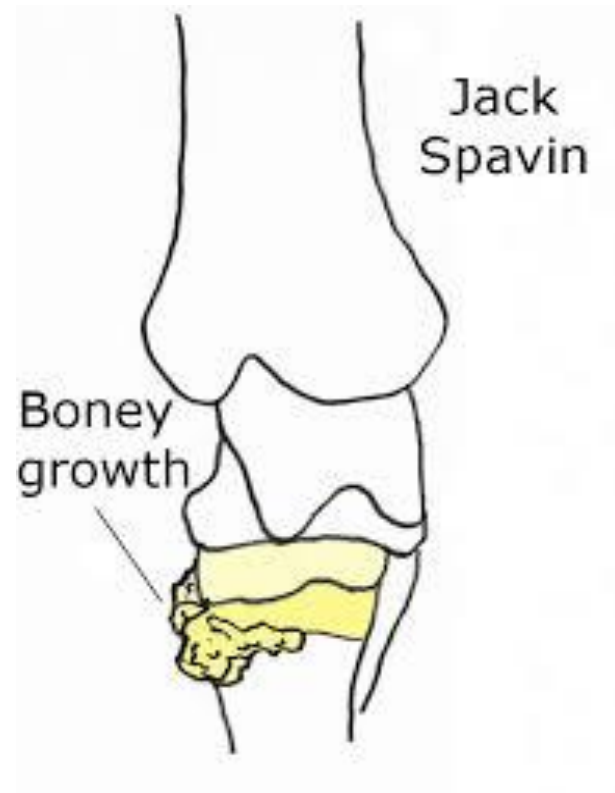


Fig. 4. Joint capsules of the digit: 1, metacarpophalangeal joint; 2, proximal interphalangeal joint; and 3, distal interphalangeal joint. (Courtesy of Andrew Parks, VetMB, MS, MRCVS, University of Georgia, Athens, GA)

2. Splint: This is exostosis at the end of metacarpal or metatarsal bones. It is not usually painful and so no lameness seen



3. Spavin: This is exostosis on the medial portion of the distal tarsal bones. This causes lameness as the bony growth pinches the cunean tendon, which passes over it.



Histopathology

- The exostoses or osteophytes have the structure of a compact bone but do not have haversian system.
- The lesions produced by bacteria in chronic osteomyelitis are granulomas.
- In chronic osteomyelitis, centre of pus are surrounded by granulation tissue and inflammatory cells, consisting mostly of mononuclears and a few giant cells.
- Due to activity of the osteogenic layer of the periosteum new bone is formed and so the shaft is thickened and marrow narrowed- osteosclerosis .
- In actinomycosis and tuberculosis there is rarefaction of bone – rarefying osteitis. In tuberculosis, there is extensive destruction of bone with the formation of caseous material but new bone is not formed.

Fracture

Definition

- A fracture is a break in the continuity of a bone and is usually due to trauma.

Varieties of the fractures

Simple fracture	Fracture of bone without an opening over the overlying skin.
Compound fracture	Fracture with an opening on overlying skin.
Greenstick fracture	Here one side of the bone is broken while the other is intact as occurs when a green stick is bent.
Impacted fracture	When one fragment of a fractured bone is firmly driven into the other.
Transverse fracture	Fracture at right angles to the axis of the bone
Oblique fracture	Break extends in an oblique direction.
Linear fracture	Here bone is split lengthwise.
Multiple fractures	Here are two or more lines of fracture of the same bone but not communicating with each other.
Comminuted fracture	The bone is splintered into many pieces.
Pathological fracture	The fracture is not due to trauma only but due to some bone disease existing. e.g. Osteosarcoma.
Articular fracture	When joint surface of a bone is involved.
Depressed fracture	In the skull where the involved bone is depressed below the surface.

- **Sequelae**

- ***Healing of fracture***

- Along with fracture of bone, there is hemorrhage as the blood vessels nearby are torn and ruptured. The capillaries of the haversian canals also contribute to the hemorrhage.
- Because of ischemia (due to cessation of local circulation) bone cells die and these incite an inflammatory reaction.
- The accumulated blood clots
- **In 24 hours**, this clot is invaded by fibroblasts and capillaries from the periosteum and is organized. This fibrovascular tissue is strong enough to keep the two broken ends together and is known as a soft tissue callus . (Callus, Latin for a hard substance).
- Osteoblasts derived mostly from the deeper layer of the periosteum invade the blood clot along with the capillaries and within **4 or 5 days trabeculae are formed around** central spaces which become Haversian canals. This is the osteoid laid down by the osteoblasts.
- **This osteoid is well formed by the end of second week.**
- **Osteoblasts are also formed by metaplasia of the fibrous tissue.**
- Later calcium salts are deposited on the osteoid to form bone.
- The newly formed bony tissue unites the two ends of the fracture bone and is known as **provisional callus**.
- The callus formed by the periosteum and located sub-periosteally is called **external callus** , that present in the medullary region is called **internal callus** and that between the ends of the shaft the intermediate callus or in-line callus .

- The callus formed is larger than the outline of the bone and so bulges on the periosteal side.
 - In the beginning there is no orderly arrangement of the trabeculae and haversian systems.
 - Later the provisional callus is removed by osteoclasts and remodeled by osteoblasts into regular bone. This is called definitive callus .
 - It may take several months for this definitive or hard callus to form.
 - Finally during the remodeling processes, excess of the callus is removed.
- If the gap between the two ends of a broken bone is too wide, the fibroblasts of the provisional callus may become cartilage cells by metaplasia and this is later converted into bone – **endochondral ossification**

Factors that interfere with healing

- **Non-alignment of the two ends of the bone:** Due to this deformity, excessive callus formation and displacement of bone may occur.
- **Inadequate immobilization:** A false joint or pseudoarthrosis may occur if the fractured ends are not firmly immobilized. The provisional callus is not sufficiently mineralized and so permits bending at the fracture area.
- **Fragments of necrotic bone:** This is more common in comminuted fractures where the necrotic bone acts as a foreign body producing inflammation and prevents healing.
- **Presence of foreign bodies hinders normal and rapid healing.** These may be bullets, muscle, fat or clothing.
- **Infection:** This is common in compound fracture, leading to necrosis and osteomyelitis, which retard the process of healing.
- **Senility:** In older animals healing is slow due to decreased vascularity and retarded metabolic processes.
- **Deficiency of calcium, phosphorus, vitamin D and proteins:** These may occur in dietary deficiency, starvation, metabolic or infectious diseases e.g. renal diseases, malabsorption diseases due to gastro-intestinal pathology, parathyroid disorders and excessive loss of protein as in albuminuria or heavy stomach worm infections.
- **Pathological:** Presence of osteodystrophy or neoplasms prevents healing of fractures.

TUMORS OF BONE

- Primary tumours of bone include fibroma, myxoma, lipoma, chondroma, osteoma, chondrosarcoma, fibrosarcoma, osteogenic sarcoma, and giant cell tumor.
- Secondary tumours of bone are metastatic carcinoma and sarcoma from other parts of the body.

Arthritis

- Inflammation of the joint is called arthritis.
- **Terminology**
- Inflammation of hip joint**Coxitis**
- Inflammation of stifle joint**Gonitis** .

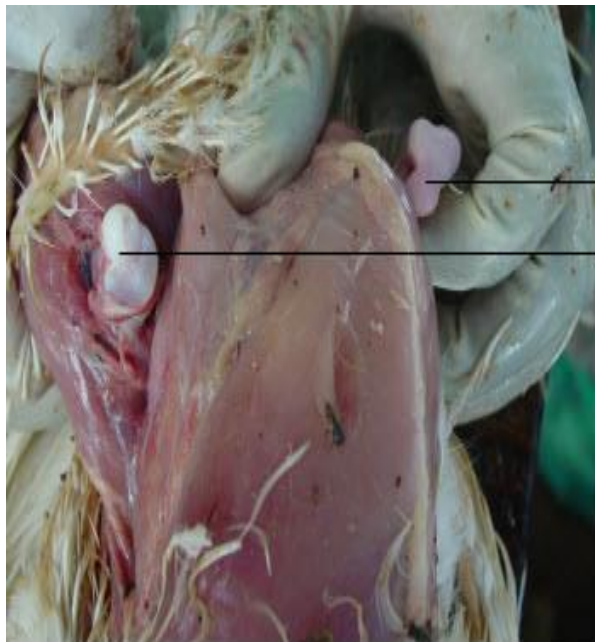
- **Types**

- Based on course: Arthritis may be acute or chronic.

- Based on etiology: Bacterial

- **Gross lesions**

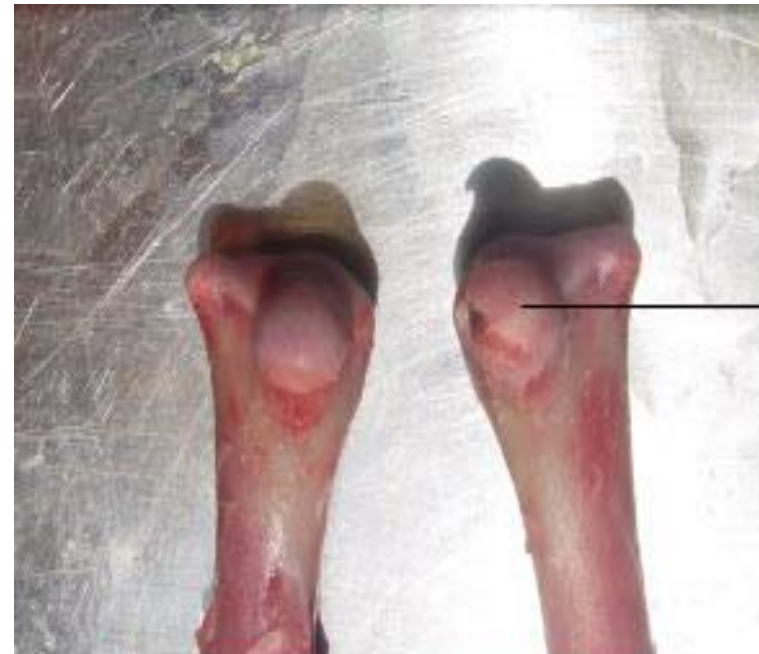- In case of chicken, affected with staphylococcal infection, calcium deficiency and reoviral infections, the articular cartilage of femur may be eroded



→ Femur head without articular cartilage

→ Normal femur head with articular cartilage

Unilateral femoral head necrosis - Chicken



→ Femur head without articular cartilage

Femoral head necrosis - Chicken

Acute arthritis

- ***Etiology***

- Contusion or strain in which there is stretching of the joint capsule.
- Bacteria: Routes of infection may be (a) via blood stream (b) by extension from neighbouring tissue and (c) by puncture wounds.

- ***Gross pathology***

- Trauma usually produces a serous type of inflammation in which there is increased production of synovia distending the joint capsule.
- The condition is mild showing a slight hyperemia of the articular cartilage and the synovial membrane.

Bacterial artheritis

- Bacterial arthritis is classified as
 - Non-suppurative and
 - Suppurative
- **Non-suppurative arthritis**
- In non-suppurative arthritis, there is acute serous or serofibrinous exudate.
- ***Etiology***
 - The causes are
 - *Erysipelothrix rhusiopathiae* (serous polyarthritis) in sheep and pig
 - *Hemophilus influenzae suis* in pig.
- ***Gross pathology***
 - The exudate contains yellowish flakes, which are often compressed into flat structures which float in the joint fluid.
 - The Synovial membrane is thickened and studded with hemorrhages.
- ***Histopathology***
 - Synovial membrane: hyperemia and neutrophilic infiltration are common.
 - Articular cartilage may be eroded.

Suppurative arthritis

- ***Etiology***

- This condition is usually associated with Navel ill.
- The bacteria localize in the joints because of the rich blood supply there and also probably to the weak defenses in that region.

- ***Routes of infection***

- Infection may be
 - Primary through penetrating wounds of joints.
 - Secondarily by extension of suppurative process from neighbouring lesions or metastatic lesions in pyemia.
- The following organisms are incriminated

Animal affected	Causative bacterium	Nature of lesions
Calf	<ul style="list-style-type: none"> • E. coli • Corynebacterium pyogenes 	<ul style="list-style-type: none"> • Purulent arthritis with destruction of joint. • Organisms may be found in pure culture or mixed with other organisms Septicemia and acute arthritis • Synovia is cloudy • Many organisms are present in the joint.
Colt	<ul style="list-style-type: none"> • Shigella equirulis • Streptococci 	<ul style="list-style-type: none"> • Swollen joints • Purulent exudate
Sheep	<ul style="list-style-type: none"> • Staphylococci • Brucella abortus 	<ul style="list-style-type: none"> • Purulent exudates with joint destruction
Swine	<ul style="list-style-type: none"> • Streptococci • Brucella abortus 	<ul style="list-style-type: none"> • Purulent exudate

- ***Gross pathology***

- The affected joint is swollen.
- Sometimes, the pus in the joint may be discharged through a break in the skin resulting in an open joint .
- Synovial fluid is purulent. White yellow green pus may be present in the joint depending on infective organism. In mycoplasma infection, pus is thin and colourless.
- Particles of disintegrated bone are found in the pus like grains of sand.
- The articular cartilage may be inflamed and eroded.
- There may be inflammation of the periarticular tissue.

- ***Histopathology***

- Microscopically, there is infiltration by neutrophils.

- ***Sequelae***

- The condition has unfavorable prognosis in young animals. Due to pain, they will not be able to move about.
- In suppurative arthritis the articular cartilage is destroyed and infection may spread to the underlying bone leading to suppurative osteomyelitis, necrosis and caries of bone.
- If the condition becomes chronic, there is excessive fibrosis and ankylosis of the joint.

Chronic arthritis

- Etiology
- Chronic arthritis may be a sequel to acute arthritis.
- Primary
 - Chronic trauma to a joint
 - Bacterial: Tuberculosis in ox and pig; Fowl Cholera in fowls.
- In chronic stages of fowl cholera, *Pasteurella avium* may get localized in the joints and tendon sheaths.
- **Gross pathology**
- There is an accumulation of a cloudy or cheesy material giving the joint a swollen appearance.
- **Chronic serous arthritis**
- Due to destruction of the articular cartilage, there may be fibrous adhesion between the articular surfaces.
- Subsequently the two bones may fuse together producing ankylosis of the joint.

- Tuberculous arthritis
- Tuberculous arthritis is characterized by the granulomatous inflammation.
- It is manifested in 3 forms.
 - *Miliary form*
 - Here military nodules are found in the synovial membrane.
 - The neighbouring tubercles may coalesce and project into the joint cavity as ‘pearls’.
 - This form is seen in pigs.
 - *Infiltrating tuberculosis* (Chronic organ tuberculosis)
 - This is seen in cattle characterized by diffuse tuberculous granulation tissue containing epithelioid cells and giant cells.
 - *Caseating tuberculosis*
- It is characterized by synovitis with caseation but without specific granulation tissue

- Mycoplasmal arthritis in swine
- ***Etiology***
 - Mycoplasma granularum is a common cause of arthritis in 100 to 200 pound swine.
- ***Predisposing causes***
 - Stress
 - Heavy muscling
 - Genetical background
- ***Pathogenesis***
 - The disease is usually an acute one, with sudden onset of lameness.
 - The course runs for 3 to 10 days.
 - Subsequently flare up cause longstanding chronic arthritis.
- ***Gross pathology***
 - In the acute form, there is increased serosanguineous synovial fluid in the femuro-tibial, coxo-femoral, cubital or scapulohumoral joints.
 - The synovial membranes are swollen, hyperemic and discolored but the joint capsule and articular surfaces appear normal.
- ***Histopathology***
 - Microscopically, in the synovial membrane, hyperplasia of synovial lining cells, villous hypertrophy and extensive mononuclear infiltration are noticed.

Degenerative arthropathy

- **Synonym**
- Osteoarthritis-deformans
- **Definition**
- In arthropathy, no inflammation occurs initially, but is an ageing process.
- This condition should be distinguished from the conditions of joint resulting from arthritis.
- **Etiology**
- The following causes are incriminated
 - Probably it is an ageing process.
 - Faulty circulation.
 - Obesity
 - Absorption of products of faulty digestion.
 - Repeated trauma as in concussion sustained by working horses on hard road; sprains.

Pathogenesis

- The cartilage being avascular depends on the synovial fluid for its nutrition. So, many changes that may occur in the synovial fluid as a result of ageing process may contribute to the degeneration of the cartilage.
- To start with, cartilage cells undergo hydropic degeneration and fatty changes.
- The fibrils of the cartilage become visible.
- Subsequently fissures form on the cartilage followed by fibrosis of the ground substance.
- The cartilage soon becomes separated and eroded, exposing the bone underneath.
- The older cartilage has lost its power of regeneration and growth and so repair does not occur.
- When ulceration of the cartilage occurs, the bone is exposed and subjected to stress and becomes sclerosed and hard (eburnation).
- Granulation tissue grows from the exposed bones of the two articular surfaces and thus fills the articular cavity. This tissue subsequently becomes ossified resulting in ankylosis. At the margin or edges of the joint are formed periostitic exostoses.
- The Synovial membrane becomes fibrous and thickened.
- The villi become thickened, fibrous and long and contain fatty tissue.
- Occasionally near the area of degeneration, some cartilage cells proliferate and form into small nodules which may be calcified following degeneration. These nodules may become detached into the articular cavity.

Ring bone

- **Definition**

- This is a condition of degenerative arthropathy affecting the interphalangeal articulation of horses, resulting in ankylosis and lameness.

- **Pathogenesis**

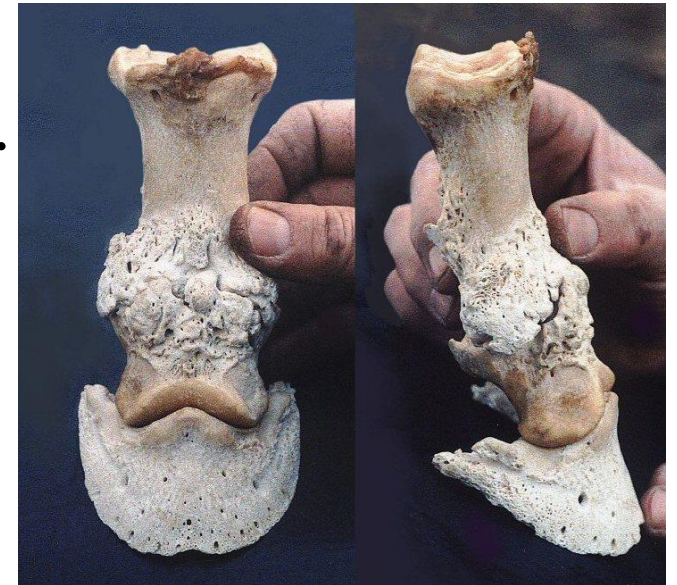- In this condition, the articular cartilages may be destroyed resulting in ankylosis. This is due to union of the articular ends

of the bones by granulation tissue which becomes ossified.

So, ankylosing arthrosis results-articular ring bone.

- More often there is chronic inflammation of the periosteum and the ligamentous apparatus due to repeated concussion and this results in periarticular

ring bone, in which the exostoses may fuse bridging the joint and fixing it.



SPAVIN

- **Definition**

- This is arthropathy of the tarsal joint affecting its dorsal and medial parts. Anklyosis may result.

- **Pathogenesis**

- The condition first starts with degeneration of the cartilages of the second and third tarsal bones. Subsequently other tarsal and metatarsal bones may be involved.
- The normal white or bluish cartilage undergoes degeneration, becoming opaque and fibrous. It breaks down and ulcerates.
- Granulation tissue from the exposed bone grows and fuses with that growing from the opposite end. When this becomes ossified, the joint becomes ankylosed. No peritarticular changes may be noticed. So such a condition is known as occult spavin.
- In some cases, the synovial membrane may become thickened due to irritation.
- The fibrous layer of the articular capsule proliferates and then becomes ossified, resulting in large exostoses, which can be easily seen on the internal and medial aspects of the hock joint.
- These exostoses pinch the cunean tendon and so pain may be caused, resulting in lameness.

ANKLYOSING SPONDYLOSIS

- **Definition**

- In this condition, the small vertebral articulations become ankylosed.

- **Pathogenesis**

- In the dog it is due to the protrusion of the nucleus pulposus irritates the periosteum and the ventral spinal ligament resulting in exostoses which may subsequently fuse and join the vertebrae.
- In bulls also this condition is met with in those that are used for stud. Due to frequent trauma attendant on their work, there is constant irritation. The lumbosacral region is more often affected causing paralysis or ataxia.

PROTRUSION OF INTER - VERTEBRAL DISCS

- Animals affected
- This condition is met with in man and dog
- Anatomical features
- Normally, the Intervertebral disc consists of a central nucleus pulposus which is semisolid mucoid connective tissue. This is enclosed in a thick fibrous covering, the annulus fibrosus.

• **Pathogenesis**

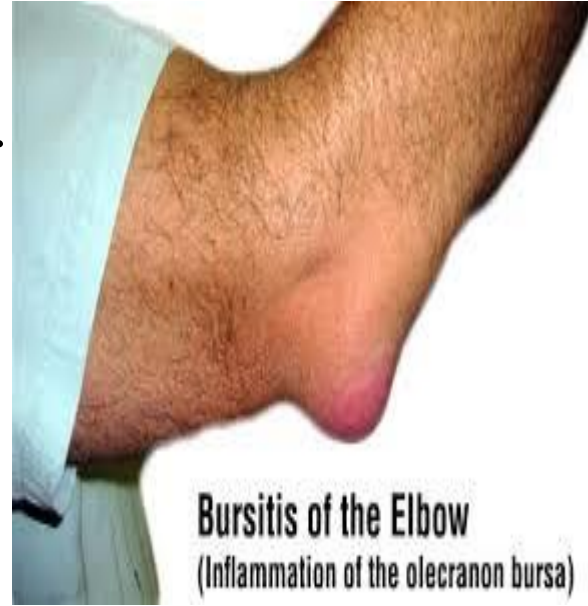
- Due to violent trauma and degenerative changes in senility, there may be a rupture in the annulus, from which the nucleus pulposus escapes and becomes displaced.
- The susceptibility of the disc to degeneration is inherited.
- Usually two forms of displacement occur:
 - dorso-lateral prolapse of the nucleus pulposus into the spinal canal.
 - ventral prolapse beneath the spinal ligaments. In this variety due to formation of osteophytes ankylosing spondylosis results.
- In the chondrodystrophic breeds (Dachshunds, Pekingese, French bull dogs) at a very early age, the nucleus pulposus become cartilaginous, which later becomes degenerated and calcified.
- So the nucleus puposus, which is normally a gel and so able to withstand shocks and transmits pressures uniformly to the annulus fibrosus, becomes transformed into a cheesy mass which crumbles easily.

- This material transmits pressure to localized portions of the annulus, which also undergoes degeneration. Its lamellae become hyalinised and later split.
- The protrusion of the disc may occur at any level, but occurs more frequently in the lumbar region or in the posterior thoracic region.
- The displaced nucleus pulposus presses upon the spinal cord producing nervous lesions.
- Pressure on the spinal cord may produce hemorrhage and necrosis in the involved area.
- Wallerian degeneration of the nerves may be noticed in the spinal nerves arising from the affected region as well as demyelination of nerve tracts.
- In other breeds, the above changes occur in mid or later life.

- **Clinical signs**
- Violent reaction to stimuli-spastic type; Pain with exaggerated reflex movements which may be intermittent or occur over long or short periods.
- Rapid progressive complete or partial paralysis of the posterior region may be noticed.
- Early death due to respiratory failure.

Bursitis

- **Definition**
- Inflammation of the bursa over the joint is bursitis.
- **Occurrence**
- This is of frequent occurrence in animals.
- **Examples:**
- Hygroma of the carpal joint in cows
- Capped elbow or hock joints of horses.
- **Etiology**
- Over-use
- Trauma, especially if repeated.
- Infection (Brucella infection in cows produces hygroma and in horses “ fistulous withers” and “ poll evil ”)
- **Gross pathology**
- The inflammation may be serous, serofibrinous or purulent.
- Trauma produces serous type - one example is the serous bursitis of hock joint in the horses. This is called Bog spavin .
- Here the joint is filled with serous fluid.

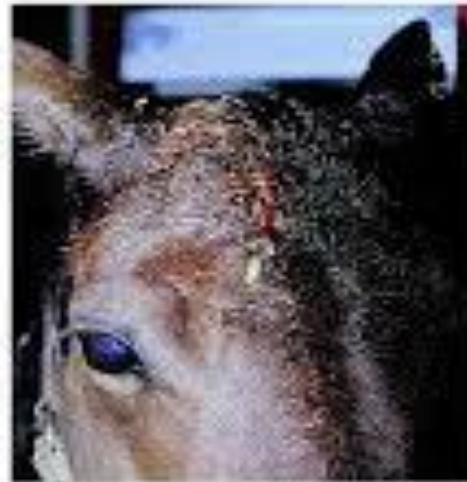

POLE EVIL

- It is the inflammation of the bursa between ligamentum nuchae and atlas and axis.

Poll Evil

- Poll Evil is a severe, pus filled swelling of the general area of the poll, accompanied by an infection of the bacteria *Brucellus abortus*



FISTULOUS WITHERS

- **Definition**

- It is the affection of bursa between the ligamentum nuchae and the thoracic spines.

- **Etiology**

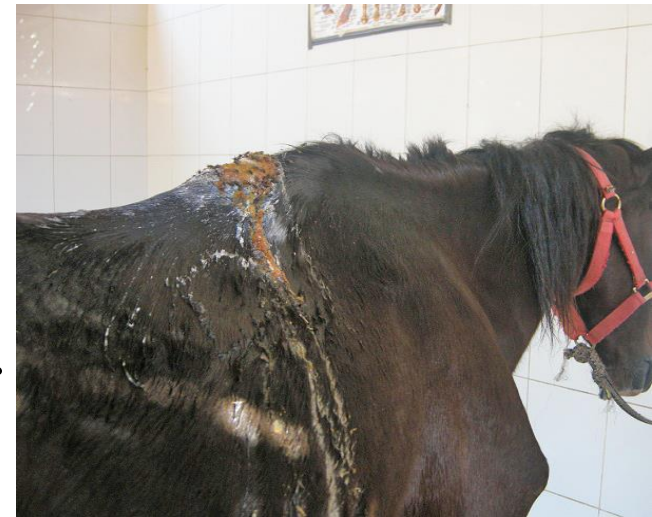- Causes may be traumatic, parasitic (*Onchocerca cervicalis*) or *Brucella abortus* and *Actinomyces bovis*.

- **Pathogenesis**

- The suppurative and granulomatous reaction is attributed to the two organisms and the infection occurs hematogenously.

- **Gross pathology**

- The inflammation is a suppurative granulomatous one in which fistulae open on the surface of the skin.



NAVICULAR DISEASE

- **Definition**

- This is bursitis and arthritis involving the distal sesamoid or navicular bone in the horse.

- **Clinical signs**

- Usually the fore limb is affected.

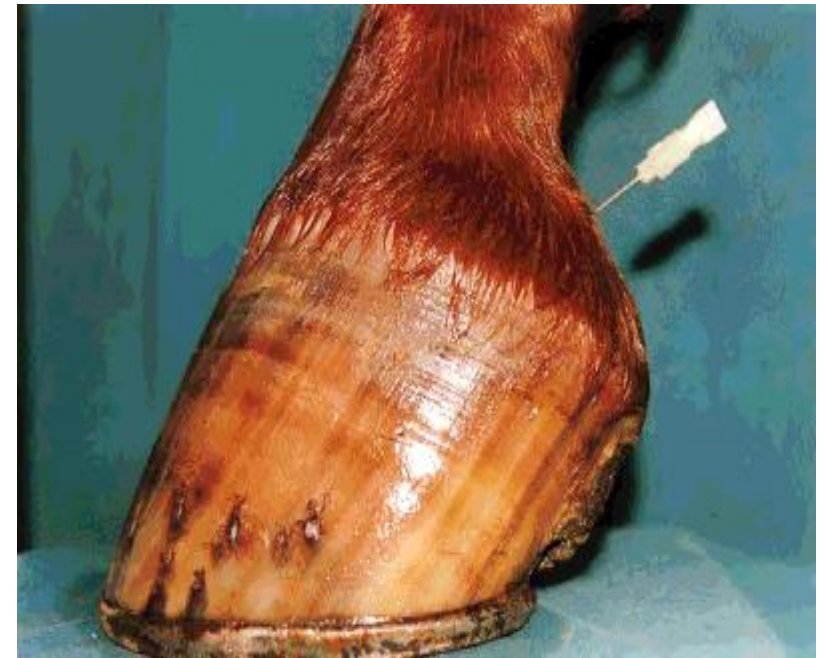- **Pathogenesis**

- First there is serous inflammation of the lining membrane of the podotrochlear bursa, with hyperemia.

- This is followed by erosion and ulceration of the articular cartilage, over which the flexor tendon passes.

- Due to the changes in the cartilage, the tendrils of the tendon become frayed and ultimately rupture of the tendon may occur.

- Later the bone is inflamed, becomes rarefied and may fracture.



INFECTIOUS SYNOVITIS OF CHICKEN

- Introduction
- This is a chronic disease of chicks.
- Etiology
- *Mycoplasma syoviae* and *Mycoplasma gallisepticum*.
- Pathogenesis
- Infection occurs in chicks, 12-14 weeks of age, by ingestion and the incubation period is 24 to 80 days.

- **Clinical signs**
- Morbidity and mortality are low.
- Emaciation
- Retarded growth
- Pale comb
- Distended hock joints
- Swollen foot pads
- Lameness.
- **Gross pathology**
- In the early stages, creamy exudate is found in the synovial membrane of the joints, especially those of the hock and foot.
- This material becomes caseous as the disease progresses.
- The surface of the affected joints becomes yellow or orange.
- In the early septicemic stage, the spleen, liver and the kidneys may be swollen.

- **Histopathology**
- The following changes are noticed microscopically
 - The characteristic lesion is a purulent synovitis of the leg joints.
 - In the liver and spleen there is proliferation of the reticular cells of the reticulo endothelial system.
 - Bile duct proliferation
 - Fibrinous pericarditis
 - Sometimes a focal infiltration by mononuclears necrosis of the myocardium
 - Thymus and bursa of Fabricius may be atrophied due to degeneration of lymphoid tissue.
 - Brain may show gliosis and degeneration of Purkinje cells.
- **Sequelae**
- With timely treatment using antibiotics the disease can be cured.

DISEASES OF SKELETAL MUSCLE

Atrophy of skeletal muscle

- **Etiology**

- *Senility*

- In old age there is gradual atrophy of all muscles.
- In dogs, milch cows, horses and ewes which are allowed to grow old, atrophy may be observed.
- It is likely that there may be under nutrition or the animal is not able to metabolise available nutriment in old age.
- The muscle cells are not able to assimilate the nutrients and so catabolism exceeds anabolism.

- ***Disuse***
 - This is seen in fractures of bones when the parts are immobilized for long periods and the muscles therefore are not utilised.
 - Disuse of the limb may occur due to pain as in rupture of a tendon, acute arthritis, ankylosis and disease of the bones and muscles.
- ***Starvation***
 - Here sufficient food is not available to make up for the catabolism that takes place.
- ***Atrophy of wasting diseases, cachexia and malnutrition***
 - In chronic wasting diseases like tuberculosis and Johne's disease; in debilitating conditions like neoplasia; in cachexia and in malnutrition, the food digested is either not effectively metabolized or is not used by the body and so atrophy results.
- ***Pressure***
 - Continuous pressure on the muscle, producing ischemia locally and interfering with movement will cause atrophy.
 - The cause of pressure may be tumors, abscesses, cysts, ill fitting collars and saddles as well as infiltration of lymphoid cells in neoplasm of these cells.
- ***Denervation***
 - When a nerve is injured or severed, the muscles supplied by it become paralysed and atrophied
 - Examples
 - Atrophy of laryngeal muscles when the recurrent laryngeal nerve is injured (Roaring)
 - Atrophy of supraspinatus muscles when the supracapular nerve is injured.
 - Atrophy of muscles in lesions of the central nervous systems - poliomyelitis, protrusion of intervertebral disc, tumors etc.

- **Gross pathology**

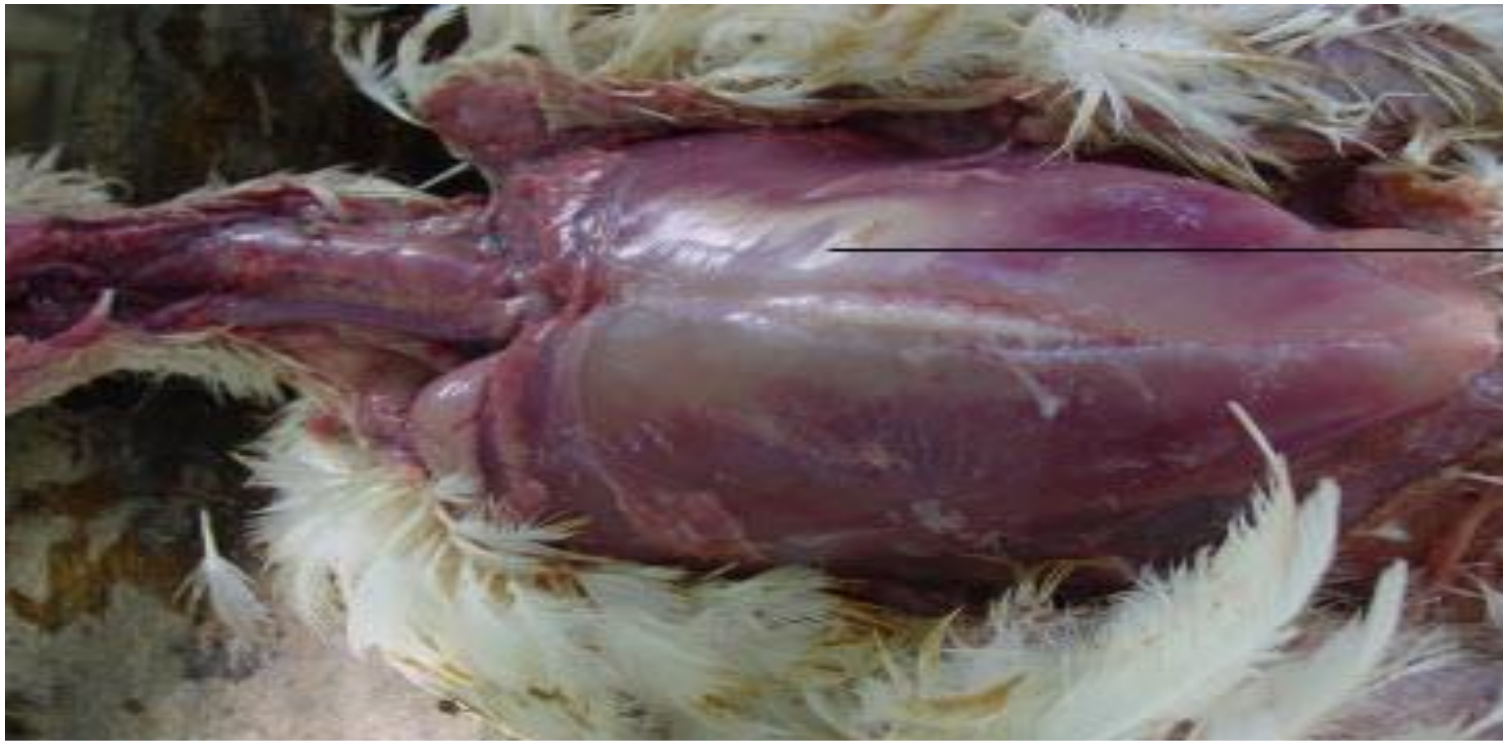- The muscle which is normally pink, loses this color and turns pale, grey or brown.
- It is firmer due to replacement by fibrous tissue.
- Due to uneven atrophy of different muscles, disfigurement may occur.
- Skeleton becomes prominent.

- **Histopathology**

- The size of the muscle fibres is reduced.
- Sarcoplasm may become so reduced and in some places may even disappear, that the sarcolemmal nuclei become prominent.
- There may be deposition of “wear and tear” pigments at the poles of nuclei giving the muscle a brown color-brown atrophy
- The cell nuclei may proliferate and fill the empty sheath.
- The etiological factors for atrophy also cause degenerative and necrotic changes like cloudy swelling, fatty degeneration and coagulative necrosis.
- In later stages there may be infiltration of fat in some areas (atrophia lipomatosa) and fibrosis in others.

Loss of myoglobin

Skeletal muscles may lack myoglobin in some areas as in case of Heat stroke in chicken.



Cooked up appearance of breast muscle

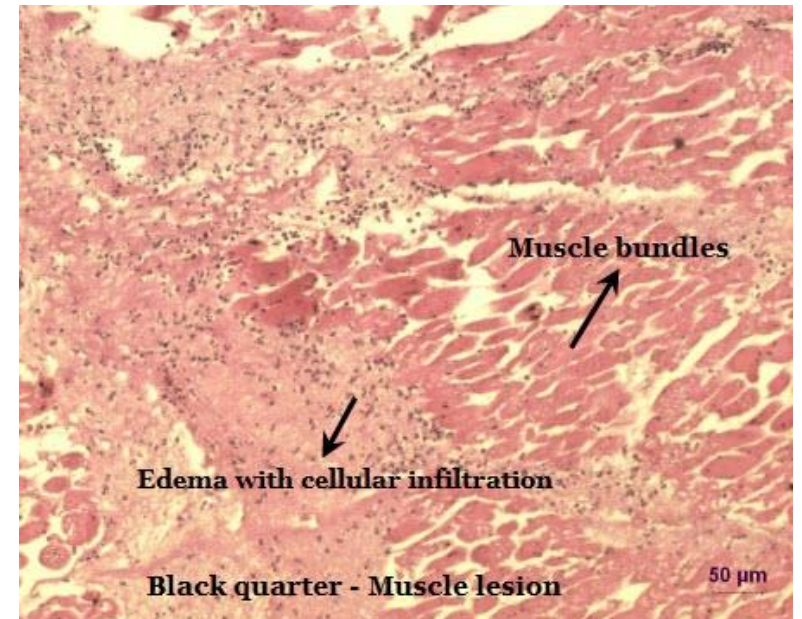
Cooked up appearance of breast muscle - Heat stroke - Broiler chicken

MYOSITIS

- **Definition**
- Inflammation of the muscle is called myositis.
- **Types**
- This may be acute or chronic.
- **Etiology**
- The routes of infection and causes are
 - Trauma
 - By direct extension from lesions of neighbouring arthritis, osteitis or periostitis
 - In pyemia, hematogenously
 - By parasitic infection.

ACUTE MYOSITIS

- Acute non-suppurative myositis
- **Etiology**
 - Best examples of acute non suppurative myositis is black quarter is cattle and sheep.
- **Gross pathology**
 - In this condition, the organisms, *Clostridium chauveoi* causes inflammation and necrosis of the muscles with production of gas.
 - Local hemorrhage is present and the area is black due to formation of black iron sulphide.
 - Regional lymph nodes are acutely congested
 - Serous cavities contain blood stained serous fluid.
- **Histopathology**
 - There is necrosis of the muscle, infiltration by neutrophils
 - and clumps of the anaerobe.
 - The muscle fibres are torn by the gas bubbles.
 - Parenchymatous organs show fatty changes



- **Suppurative myositis**

- ***Etiology***

- Infections may occur in lacerating and penetrating wounds or by extension from adjoining areas.
- Haematogenous infection may occur from other foci as in strangles and Glanders.

- ***Gross pathology***

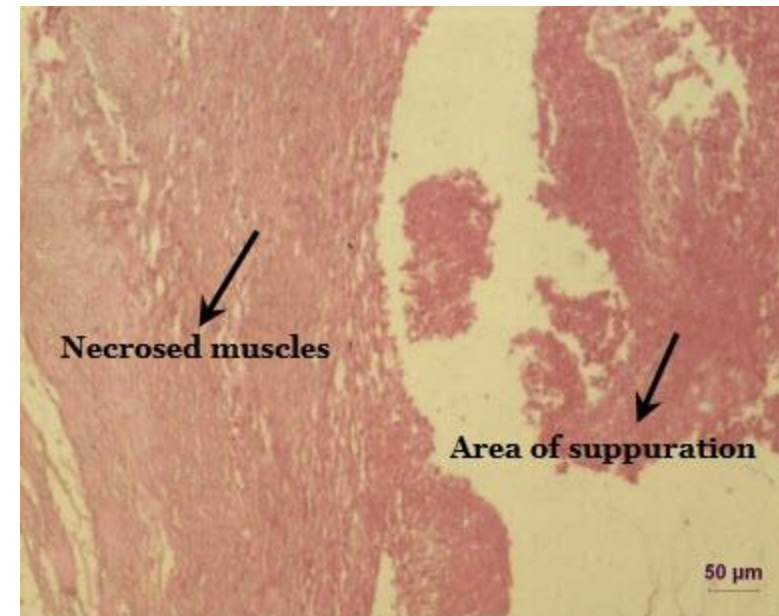
- The usual changes of suppurative inflammation are found, viz, abscess or phlegmon.

- ***Histopathology***

- Microscopical appearances are typical of any other suppurative inflammation with a great outpouring of neutrophils.
- The muscle fibres undergo liquefaction following
- coagulative necrosis.

- ***Sequelae***

- As there is loss of muscle tissue, healing is by means of
- fibrous tissue proliferation and scar formation.
- If severe, septicemia may result.



Suppurative myositis

CHRONIC MYOSITIS

- **Etiology**
- Actinomycosis
- Actinobacillosis
- **Gross pathology**
- The muscles of the tongue, cheek and throat are affected.
- **Histopathology**
- The lesion consists of chronic suppurative myositis in which the “Sulphur granules” are noticed in a mass of inflammatory granulation tissue.
- There is infiltration by large number of lymphocytes, neutrophils and plasma cells.
- Muscle fibres are destroyed.

PARASITIC MYOSITIS

- The following parasites are found to infect the muscles of animals.
- **Toxoplasma**
- **Trichinella spiralis**
 - This is found in man, pig and other animals.
 - The larvae are encysted in many muscles, especially those of diaphragm, intercostals muscles and tongue.
 - The cysts are parallel to the muscle fibres which undergo granular degeneration of the sarcoplasm.
 - Intense infiltration by eosinophils, plasma cells, histiocytes and lymphocytes occurs
 - Sarcolemmal nuclei proliferate
 - The encysted larvae may be alive for as long as 20 years.
- **Sarcosporidiosis**
 - The sarcosporidia are present in the skeletal and cardiac muscle of all species of animals.
 - No specific disease has been attributed to these parasites.
 - Though light infections cause no perceptible symptoms, heavy infections may be responsible for lameness, weakness, paralysis, emaciation and sometimes even death.
 - Parasitised muscle fibres are destroyed by the parasite and the adjacent cells undergo pressure atrophy.

- **Cysticercus (Measles)**
 - **Cysticercus cellulosae**
 - The bladder worm of *Taenia solium*, a tapeworm of man infects the muscles of pig.
 - The muscles of the shoulder, neck, diaphragm, tongue, intercostals, abdominal and cardiac muscles are affected.
 - Heavy infection may result in fatal anemia and cachexia.
 - **Cysticercus bovis**
 - It is the intermediate stage of tapeworm *Taenia saginata* of man, found in the muscles of cat.
 - All muscles may be affected but those of tongue, mastication and heart are more often infected.
- **Cysticercus ovis** is the intermediate stage of dog tape worm *Taenia ovis* and is found in the muscles of sheep

DISEASES OF UNKNOWN ORIGIN

- **Eosinophilic myositis**
- **Etiology**
- Cause: Unknown.
- Some kind of allergy
- Vitamin E deficiency.
- *Cattle and Sheep*
 - Very rarely, at slaughter, yellowish green areas may be noticed in the lingual, oesophageal, cardiac and diaphragmatic muscles of cattle and sheep.
 - The green color fades on exposure to light
 - Microscopically, large numbers of eosinophils, histiocytes, plasma cells and lymphocytes are found between the muscle fibres and in tissue spaces.
 - Though extensive degeneration of the muscles may not be noticed, in some places necrosis and invasion of muscle fibres by the eosinophils are observed.
 - In more chronic cases fibrosis is evident.
 - There is some suspicion that the condition may be a manifestation of allergy and sarcosporidia are suspected as the sensitizing factor.

- ***Dogs***
 - German shepherds and Alsatians are more often affected.
 - Clinically, the condition involves the masseter, temporal and pterygoid muscles chiefly.
 - Other muscles may be affected.
 - The muscles of mastication are enlarged bilaterally so that opening of the mouth is painful and mastication is interfered with.
 - The eyes bulge out, resulting in keratitis and corneal ulceration, since eyelids cannot close completely.
 - The local tonsillar and mandibular lymph nodes are also swollen.
 - Blood picture reveals high eosinophilic count up to as much as 90%.
 - Temporary remissions may occur but are followed by repeated attacks and the animal finally dies.
 - As the animals cannot eat, they die finally of inanition.

- **Gross pathology**
- The affected muscles are swollen, hard to the touch, show grey and red streaks and white and yellow spots.
- Hemorrhage is present.
- The regional lymph nodes are congested and swollen.
- **Histopathology**
- There is heavy infiltration of eosinophils, lymphocytes, plasma cells and macrophages into the muscle, producing atrophy, and hyaline necrosis, vacuolar degeneration and lysis of muscle fibres.
- Hemorrhage is common.
- The necrotic muscle is removed by macrophages and fibrosis follows.
- In the liver periportal lymphocytic infiltration is found

WHITE MUSCLE DISEASE

Synonym

- Stiff-lamb disease

Definition

- This is coagulative necrosis of the muscles due to various causes.

Animals affected

- The condition occurs in calves and lambs and can be produced in rabbits and guinea-pigs.

- **Etiology**

- *Vitamin E deficiency*: Vitamin E is an antioxidant and in its absence, oxidation in the muscles is increased to 400 times the normal and so degeneration and necrosis occur
- Vitamin E deficiency may occur in the following manner.
 - Dietetic deficiency.
 - Feeding too much of cod liver oil. The unsaturated fatty acids in the cod liver oil antagonize Vitamin E.
- *Selenium deficiency*: Selenium is required in minute quantities. In its absence muscle necrosis occurs.
- Selenium deficiency can occur in the following manner.
 - Deficiency in the soil; animals that are grazed on fodder grown on soils deficient in selenium suffer from the disease.
 - Excess of sulphur used in fertilizers inhibits the uptake of selenium by plants.
- *Vitamin B deficiency*: It is found that Thiamine deficiency produces cardiac necrosis. Deficiency can occur in animals when the ruminal flora is not active to synthesize the vitamin as occurs in cobalt deficiency.
- *Abnormal ruminal fermentation*: Some toxic products produced in the rumen cause muscle necrosis.
- *Deficiency of choline* produces muscle necrosis in rabbits (experimentally)
- *Vitamin A deficiency*: Vitamin A deficiency produces this disease in swine.
- *Multiple deficiencies*: In starvation as occurs during drought and malnutrition, multiple deficiencies of vitamins and minerals (phosphorous) may occur and muscle necrosis may be encountered. Similar lesions are seen in hypothyroidism.

- Types
- The clinical picture is classified into three main types.
- *The stiff type*
 - The head is carried low and has a dropping posture.
 - Animal experience difficulty in rising and walking. While walking, the gait is stiff.
 - The weight-bearing and active muscles, for example, muscles of the croup and quarters, diaphragm, heart and intercostals are mostly affected.
 - In lambs, this is the form encountered and the animals are always recumbent and do not like to move. On forcible movement, they have stiff gait and wobble. (**Stiff lamb disease**).
- *The respiratory type*
 - Here the muscles of respiration (diaphragm and intercostal muscles) are affected and the animal may show symptoms of respiratory distress.
- *The cardiac type*
 - In this type, animals show considerable weakness, inability to stand, rapid pulse and low blood pressure.
 - Since the heart is affected and weakened, exertion brings on respiratory distress and even death in animals with cardiac involvement alone
 - Sudden death occurs without any other symptoms.

- **Clinical pathology**

- Clinically the serum glutamic oxaloacetic transaminase (SGOT) level will be more than 300 units while the normal is less than 100 units.

- **Gross pathology**

- Those muscles which are continuously active, viz. diaphragm and intercostal muscles show the changes.
- The whole muscle bundle may not be affected but only a part of it will show the change.
- The muscles are bilaterally affected and are pale like fish flesh.
- The paleness is due to loss of myoglobin which is excreted in the urine. The change in color is also due to changes in optical characteristics of the muscle protein when it becomes coagulated.
- The muscles become hard and wooden
- Pneumonia, edema, hydrothorax, C.V.C of liver and hydropericardium will be seen when heart is involved.
- Heart shows yellowish or grey streaks or patches and the left ventricle is more often affected.

- **Histopathology**

- The muscles are swollen with loss of striation and with widespread hyaline degeneration. This progresses to coagulative necrosis.
- Fibres are fragmented and may completely disappear.
- Marked sarcolemmal proliferation is present.
- Some fibres may be calcified
- Infiltration by macrophages and lymphocytes is seen.
- Similar lesions may be found in the heart.
- In some places healing by fibrous tissue is evident.
- One noteworthy feature is that the nerves and C.N.S are normal without showing lesions.

Azoturia

Synonym

- Equine myoglobinuria; Monday-morning sickness; Paralytica hemogloburia

Definition

- Azoturia literally means “nitrogen in the urine.”

Clinical signs

- Azoturia is found to occur suddenly in horses going to work after complete rest for a few days but maintained on full work-rations.
- The animals suddenly stop; sweat, shiver and show great suffering from pain in the lumbar regions
- The affected muscles are those of gluteal, lumbar and femoral regions and are swollen and board-like.
- Soon the animal passes coffee colored dark-brown or black urine since it contains large quantities of myoglobin.
- Animals lie down and soon die.
- Those that survive are weak and it takes a long time for them to recuperate and for the atrophied muscles to regain their normal state.

Pathogenesis

- In normal muscle contraction, muscle glycogen is converted into pyruvic acid
- Due to inadequate oxygen 1/5 of this is oxidised to CO₂ and H₂O to liberate energy. The rest is converted into lactic acid which is converted into glycogen in the liver and used again
- When the animal is at rest but well fed, the muscles are well stored with glycogen.
- When the animal is put to work suddenly much of this glycogen is converted to lactic acid in the muscles and large amounts of this stimulate extreme contraction of the muscles, which become hard (board-like)
- In the contracted state of muscles, blood circulation is poor and so oxygen supply is reduced.
- Under this hypoxic condition, lactic acid is formed (from pyruvic acid) which still further contracts the muscles and so greater curtailment of blood flow occurs leading to still greater reduction of oxygen supply.
- Thus a vicious circle is established. The net result being that the muscles do not get sufficient amount of oxygen and nutrition, and so necrosis results.
- Necrosed muscle liberates myoglobin which is excreted in the urine.
- Large masses of myoglobin in the urine appear to produce renal blockade, renal ischemia and lower nephron nephrosis wherein the epithelium of the distal convoluted tubules as well as that of Henle's loops are degenerated some of which become necrosed and desquamated.
- This condition causes degenerative changes in the tubules and so anuria and fatal uremia results
- Death is due to renal insufficiency leading to uremia.

- **Clinical pathology**
- Urine shows granular reddish casts and few hyaline casts
- **Gross pathology**
- The affected muscles are swollen, pale and have increased amount of interstitial fluid.
- **Histopathology**
- The changes in the muscle are those of Zenker's degeneration in which the muscle becomes a homogenous hyaline mass without striation.
- The fibres may be fragmented.
- There may be disappearance of all the constituents of the muscle fibres excepting the sarcolemma and fibrous stroma. This is the cause of atrophy noticed in surviving animals.
- In animals that survive regeneration may occur but it is a very slow process.
- In the kidney lesions are found mostly in the tubules. The epithelium of the proximal tubules may be degenerated and all stages from cloudy swelling to necrosis are encountered. Desquamation of epithelium occurs. Similar changes may be noticed in the epithelium of Henle's loops and distal convoluted tubules. The lumens of the tubules may contain besides the desquamated cells masses of myoglobin. These form granular pigmented casts. A few hyaline casts may also be found.

TUMOURS OF SKELETAL MUSCLE

- **Primary**
- Rhabdomyoma, rhabdomyosarcoma, lipoma liposarcoma, fibroma, fibrosarcoma and myxoma.
- **Secondary**
- Metastases of carcinoma and sarcoma are not frequent since muscle does not afford a suitable 'bed' or soil for them to grow.
- The following may be found occasionally – Lymphosarcoma, adenocarcinoma melanoma and angiosarcoms.
-

