

**MJF COLLEGE OF VETERINARY AND ANIMAL SCIENCE,
CHOMU, JAIPUR**



DEPARTMENT OF VETERINARY PATHOLOGY

TOPIC COVERED-

1. Oral cavity
2. Salivary glands
3. Esophagus
4. Fore stomach

Oral cavity

Anomalies:– congenital disturbance in development involve one tissue or organs.

Facial clefts:– longitudinal fissure in the face.

Harelip or Chelioschisis:– fissure in the lip.

Cleft palate or Palatoschisis:– fissure in the palate.

Glossochisis:– fissure in tongue.

Harelip



Cleft palate

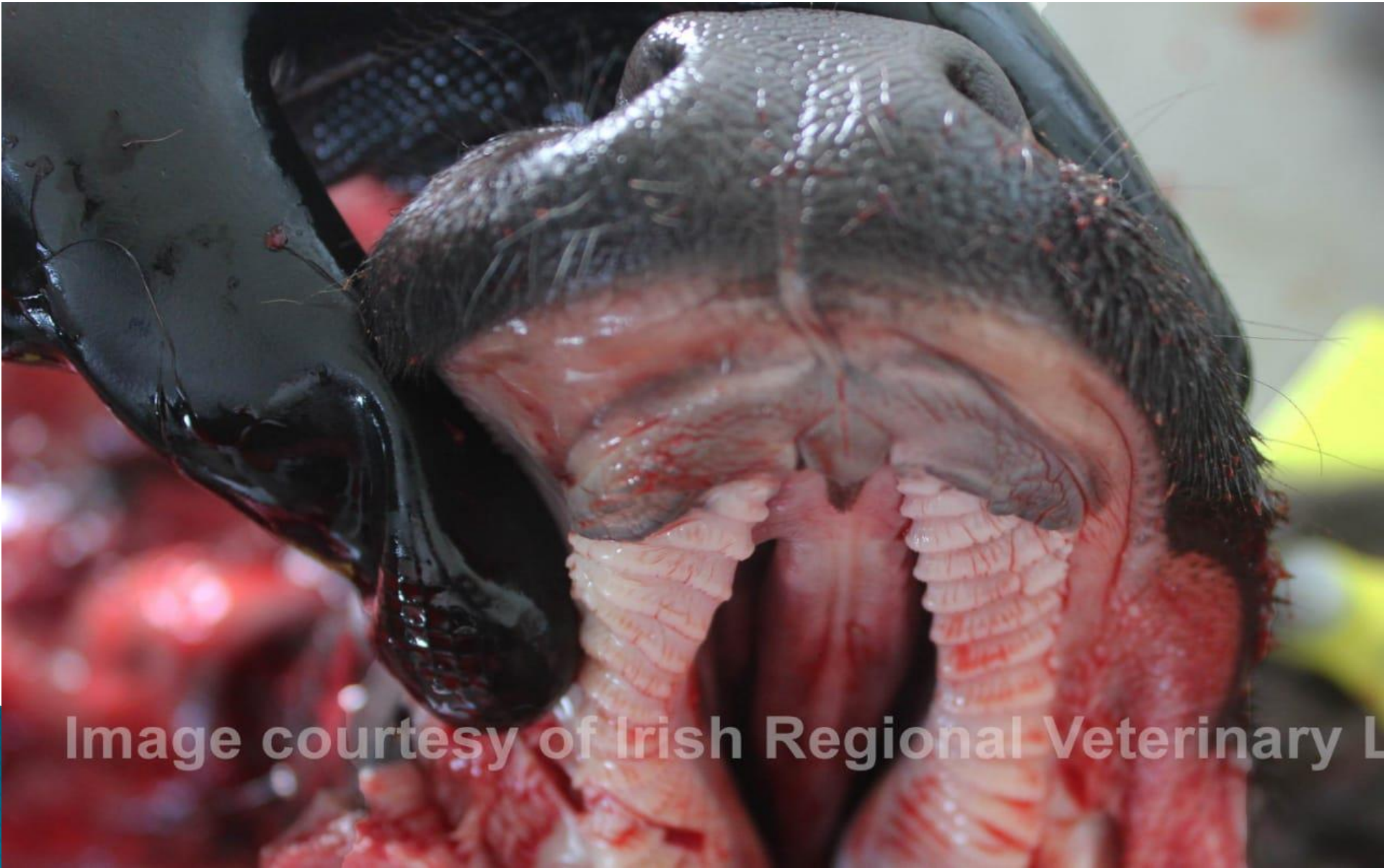

Image courtesy of Irish Regional Veterinary L

Brachygnathia:–(brachy– short, gnathia– jaw)

It is the short jaw.

1)superior– upper jaw

2)inferior– lower jaw

Prognathia:– anteriorly protruded jaw.

agnathia:– absence of jaw.

Stomatitis


- ▶ It is diffuse inflammation of the mucous membrane of the mouth.
- ▶ **inflammation confined to particular part:-**
- ▶ **GINGIVITIS**– inflammation of gums.
- ▶ **GLOSSITIS**– inflammation of the tongue.
- ▶ **LAMPAS**– inflammation of the palate.
- ▶ **CHEILITIS**– inflammation of the lips.
- ▶ **PHARYNGITIS**– inflammation of the pharynx.
- ▶ **TONSILLITIS**– inflammation of the tonsils.

Types of stomatitis–

1 According to location–

- a) Diffuse stomatitis:– due to hot drench, chemicals.
- b) focal stomatitis:– due to infectious agents.

2 According to exudate–

- a) Catarrhal stomatitis
 - b) Suppurative stomatitis
 - c) Fibrinous stomatitis
- 

3 according to lesion–

- a) Vesicular stomatitis
- b) Ulcerative stomatitis
- c) Necrotic stomatitis.

Vesicular stomatitis

- ▶ Vesicles or blebs containing fluid are formed on the mucosa.
- ▶ Examples –
 - foot and mouth disease
 - infectious vesicular stomatitis
 - infectious vesicular exanthema
 - herpes virus
- ❖ **MICROSCOPIC** – epithelium show hydropic and vacuolar degeneration.
- ▶ Rupture of vesicle results in formation of erosion with intact basal layer.

Vesicular stomatitis



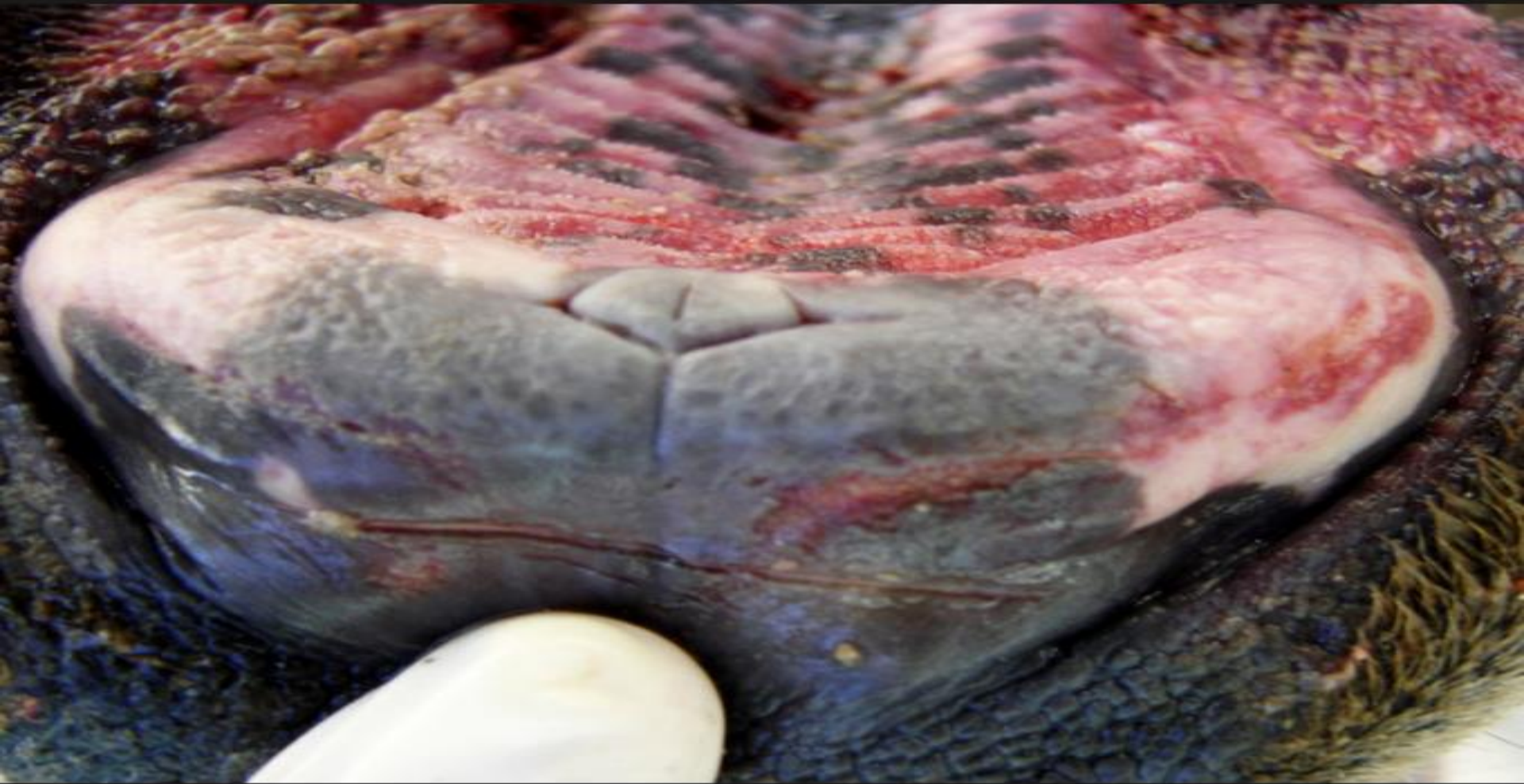Ulcerative stomatitis

▶ Etiology–


- chemical agents, acid, alkali, erosive salt
- nicotinic acid deficiency in dog(black tongue)
- Vit. A deficiency in chicks and poults
- Cattle plague
- Mucosal disease

MICROSCOPIC– discontinuation of the epithelial lining, where the base lies in the lamina propria. Ulcer is deep, red base, elevated edges and covered by epithelial shreds, healed by scar formation.

Ulcerative stomatitis



Fibrinous and necrotic stomatitis

- A. **Fibrinous (croupous) stomatitis:**– it is characterized by only deposition of fibrin threads on the mucosa.
 - B. **Fibrinonecrotic (Diphtheritic) stomatitis:**– it is characterized by more or less coagulative necrosis of the mucous membrane with marked fibrinous exudate.
 - C. **Necrotic stomatitis:**– it is characterized by pure necrosis without fibrin formation.
- 

- ▶ **Etiology**–corynebacterium pyogenes and spheroptherous necropheros.
virus – fowl pox, cattle plaue
- ▶ **MACROSCOPIC**– dirty grayish and dry fibrinous membrane on the mucosa.

In necrotic stomatitis – acid and alkali shows deep irregular necrotic area in the mucosa which slough leaving ulcer.

spheroptherous necropheros produces single or rarely multiple sharply surcumscribed dirty grayish red foci.

Inflammation of different parts of digestive system

Affected part	Terminology
Salivary gland	sialoadenitis
esophagus	esophagitis
crop	ingluvitis
stomach	gastritis
intestine	enteritis
colon	colitis
caecum	typhlitis
liver	hepatitis
Bile duct	cholangitis
Gall bladder	cholecystitis

Salivary glands

- ▶ **Ptyalism**: It is excessive salivation, which occur in some specific diseases as:-
 - foot and mouth disease
 - infectious vesicular stomatitis
- ▶ **Sialoadenitis**:- It is the inflammation of salivary gland.
- ▶ **Ranula**:- These cysts are formed due to the obstruction of the salivary duct, particularly in sublingual gland of dog and cow.
- ▶ **Sialoliths**:- It is a calcium concretion formed either in the duct or in the gland itself as a result of chronic inflammation.

ESOPHAGUS

- ▶ **Choke**:- It is complete or partial obstruction of the esophagus.
- ▶ **Causes**:- Impacted masses of feed due to improper chewing, bad teeth and rapid gulping of dry feed.
Large object of food – beet root, carrot
Enlarged lymph nodes.
- ▶ In the horse choke occurs in the thoracic area. While in cattle and dog pharynx is obstructed.

Types of choke

- ▶ Complete
- ▶ Incomplete
- ▶ **Complete**:– feed will be returned and water will come out of the nostril. obstruction will cause tympany
- ▶ **Incomplete**:– will give rise to dilatation of esophagus above the obstruction, esophageal diverticulum.

Picture showing choke in esophagus



Fore stomach of ruminants

TYMPANY:– it is overdistension of rumen and reticulum with gases. Accumulation of gas, occurs when the gas is produced at too rapid rate or due to faulty eructation mechanism.

Types of bloat–

- 1) acute bloat
- 2) chronic bloat

ACUTE BLOAT–

this may be due to choke in esophagus. Or it may also be due to sudden changes of feed or to excessive feeding on legumes that are wet with dew or rain.

CHRONIC BLOAT

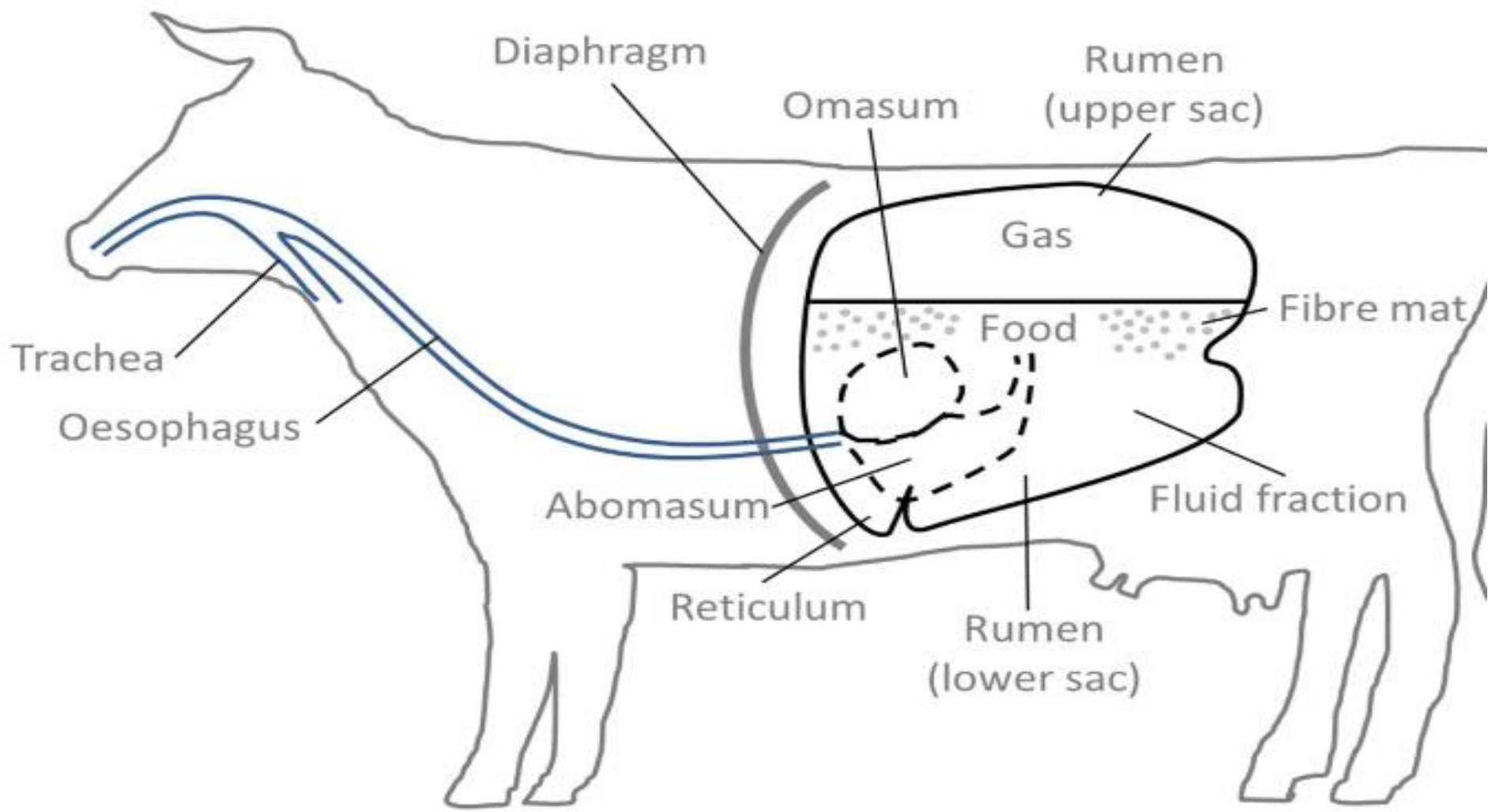
- ▶ This occurs whenever there is any hindrance to eructation in the esophagus either within or without pressure by tumors, foreign bodies, enlarge lymphnodes.

Free gas and frothy bloat


- ▶ **FREE GAS BLOAT**– this form is less harmful since in this condition the gases can be more easily got rid of by eructation.
- ▶ **FROTHY BLOAT**– the gas is trapped as small bubbles in the fluid forming a foamy mass, which is not easily eructated.

Causes– saponin containing plants and green legumes.





Clinical findings–

- ▶ Distended rumen, which compresses other abdominal organs
 - ▶ Compression on lungs cause hypoxia, asphxia and death.
 - ▶ **gross findings**– the rumen is overdistended with gases.
 - ▶ Sever congestion in all organs
 - ▶ Cyanosis of mucus membrane
 - ▶ Petechial hemorrhages on serous membrane
 - ▶ Dark unclotted blood.
- 


Impaction of rumen and reticulum

- ▶ **Impaction**– overdistention of the rumen with indigestible food and without or with little gas production. Death occurs due to toxemia.


CAUSES–

- ▶ over feeding on concentrates.
 - ▶ Atony of the musculature of the forestomach.
- 

Pathognomonic lesions–

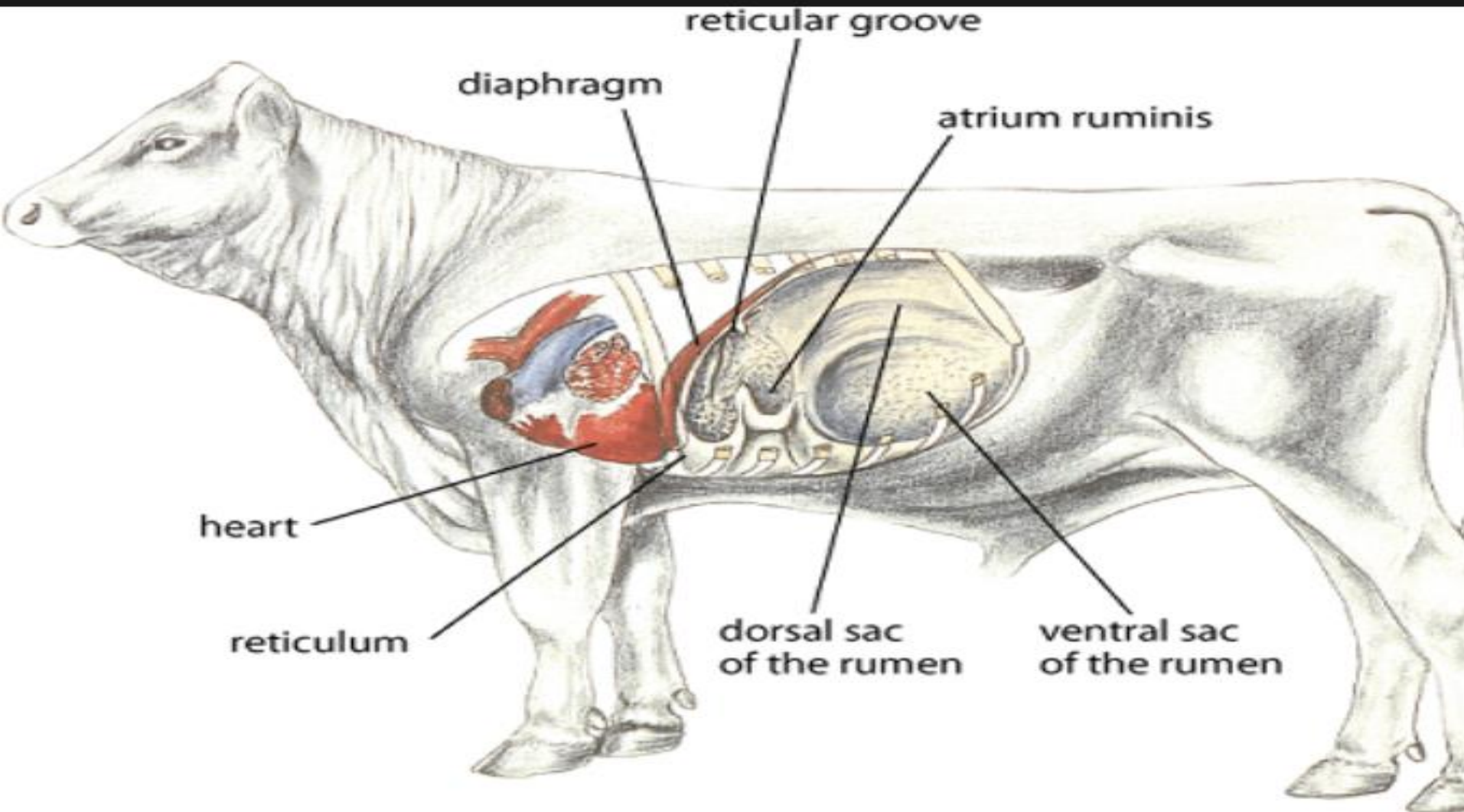
- ▶ The ruminal content has fetid odor.
 - ▶ Weakness of the ruminal wall and easily folded.
 - ▶ Severe congestion in all organs.
- 

Traumatic reticulitis–

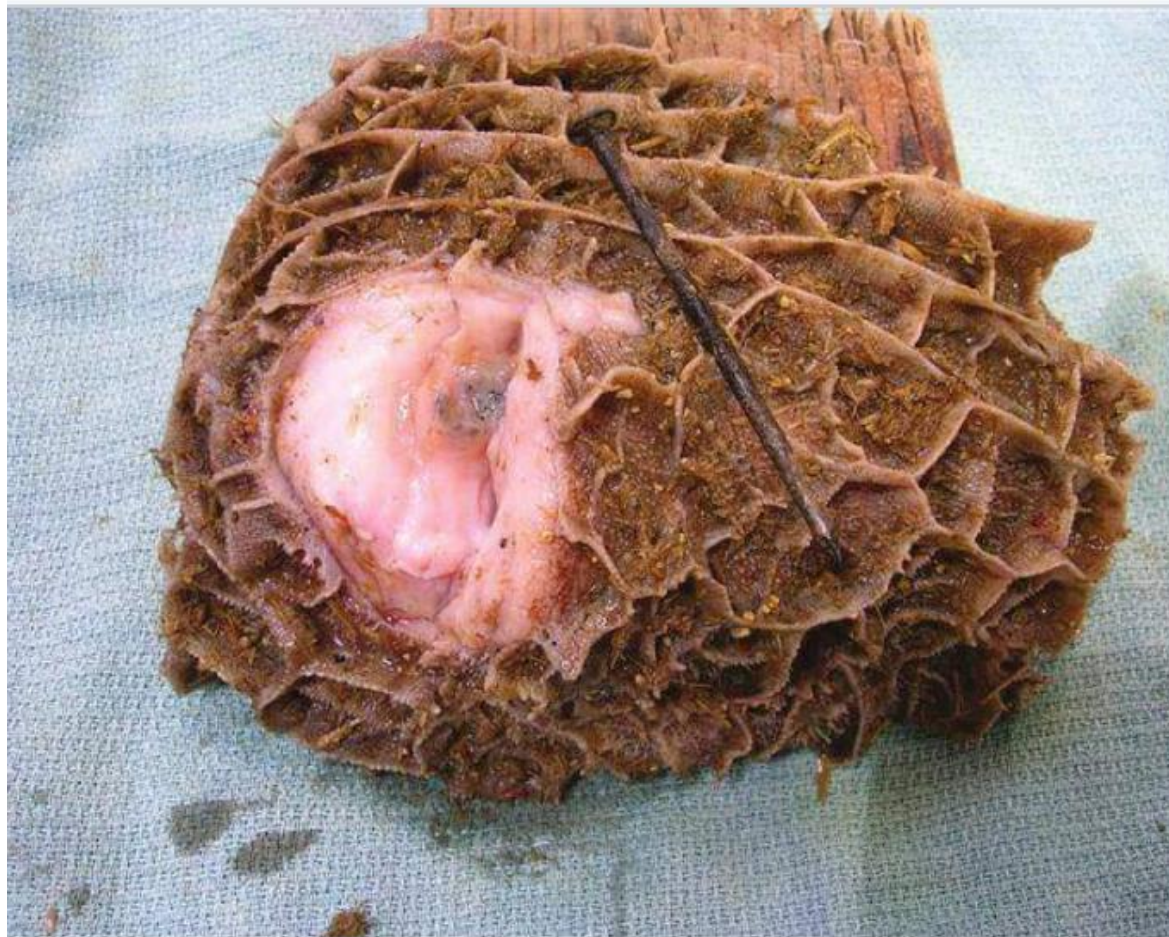- ▶ Animals ingest the sharp objects like needles, nails, piece of fencing wire and screws, along with their feed.
 - ▶ Contraction of the rumen and reticulum during pregnancy may aid in the development of condition.
 - ▶ Sharp object pierces the wall of reticulum during its contractions.
 - ▶ It pierces the antero–ventral wall which is near the diaphragm.
- 

- ▶ The foreign body may enter the pericardium and even the heart, producing inflammation enroute.
- ▶ **Gross finding-**
- ▶ thick walled track followed by foreign body.
- ▶ Point where the object pierces the reticulum localized peritonitis formed.
- ▶ Adhesion between reticulum and diaphragm.
- ▶ Some time sharp object may penetrate lung, liver or spleen.
- ▶ **Sequelae of TR-** vagus indigestion, diaphragmatic hernia.

Anatomical position of reticulum responsible for piercing diaphragm and heart



Picture showing sharp foreign object in reticulum



Thank you !

