



Department of Veterinary Physiology

MJF College of Veterinary & Animal Sciences,
Jaipur, Rajasthan- 303702

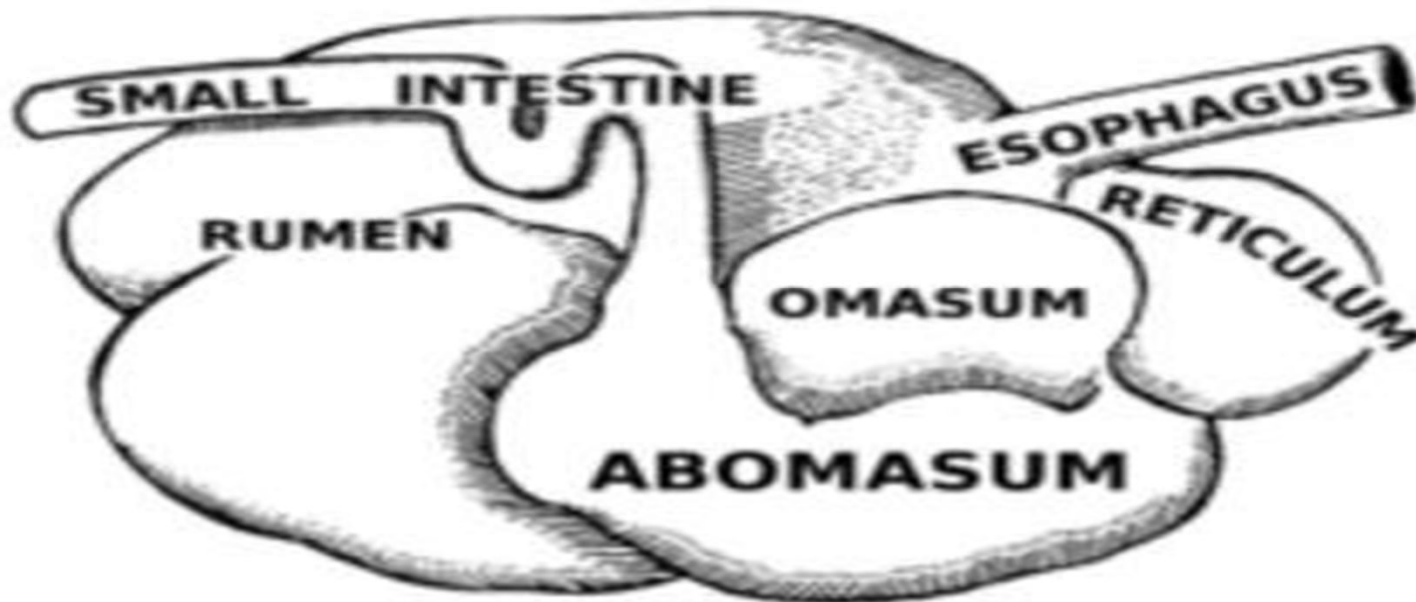
B.V.Sc. & A.H.

1st Year (2023-24)

Digestive system



पशुधनं नित्यं सर्वलोकोपकारकम्।



Dr. Brijesh Kumar
Assistant Professor
Dept. of Veterinary Physiology

Dr. Sandeep Bissu
Assistant Professor
Dept. of Veterinary Physiology

Digestive system:

- Morphological characteristics of digestive system of poly gastric and monogastric animals
- Some imp. terms related to digestive system viz. Prehension, Mastication, Rumination, Vomition, Defecation
- Developmental aspects of digestion in ruminants (ecological development as well as development of the Calf Digestive System):

Morphological characteristics of digestive system of poly gastric and monogastric animals:

Ruminants: These are hoofed mammals that are able to acquire nutrients from **plant based food** by fermentating it into specialized stomach before digestion through microbial actions. Ruminants so named because they ruminate (**chew the cud**) i.e. fermented ingesta.

About 150 species of both wild and domestic ruminants are present in the world.

Parts of GIT

- Digestive system is composed of alimentary canal (GIT) and accessory glands.
- GIT consists of oral cavity, pharynx, esophagus, stomach, SI and LI.
- Accessory gland involves salivary glands, liver and pancreas
- **Oral cavity:**
- Cylindrical cavity containing teeth & tongue.
- Roof is formed by **hard palate** and posteriorly separated from nasopharynx by soft palate.
- Floor is formed by mandible
- Laterally formed by cheeks
- Functions as **prehension, mastication, insalivation, deglutition and rumination**
- Tongue is the chief prehension & taste organ in cattle (lips in sheep, goat & horse while snout in pigs)
- Teeth are hard, dense, whitish structures for chewing of food material. 4 types of teeth that are:
- Incisor teeth: Front teeth, Canine teeth: corner teeth, Premolar & Molar: cheek teeth

Cont.

- In early age, teeth are temporary called milk or deciduous teeth and in adults replaced by permanent teeth.
- Dental formula of cattle: There is **absence of incisors in upper jaw & canines in both jaws.**
- Deciduous teeth: I (0/8), C(0/0), P(6/6), M(0/0)=20
- Permanent teeth: I (0/8), C(0/0), P(6/6), M(6/6)=32

- **Pharynx:** Conical/funnel shaped musculo-membranous sac i.e. **common for both digestive & respiratory tract.**
- **Seven** openings present in pharynx as anteriorly mouth cavity (1), dorsally posterior nares (2), laterally Eustachian tubes (2), posteriorly esophagus (1) and ventrally larynx (1).

Esophagus:

- Musculo-membranous tube extending from pharynx to cardia of stomach.
- Divided into cervical and thoracic part,
- Average length is about 90 cm in cattle.

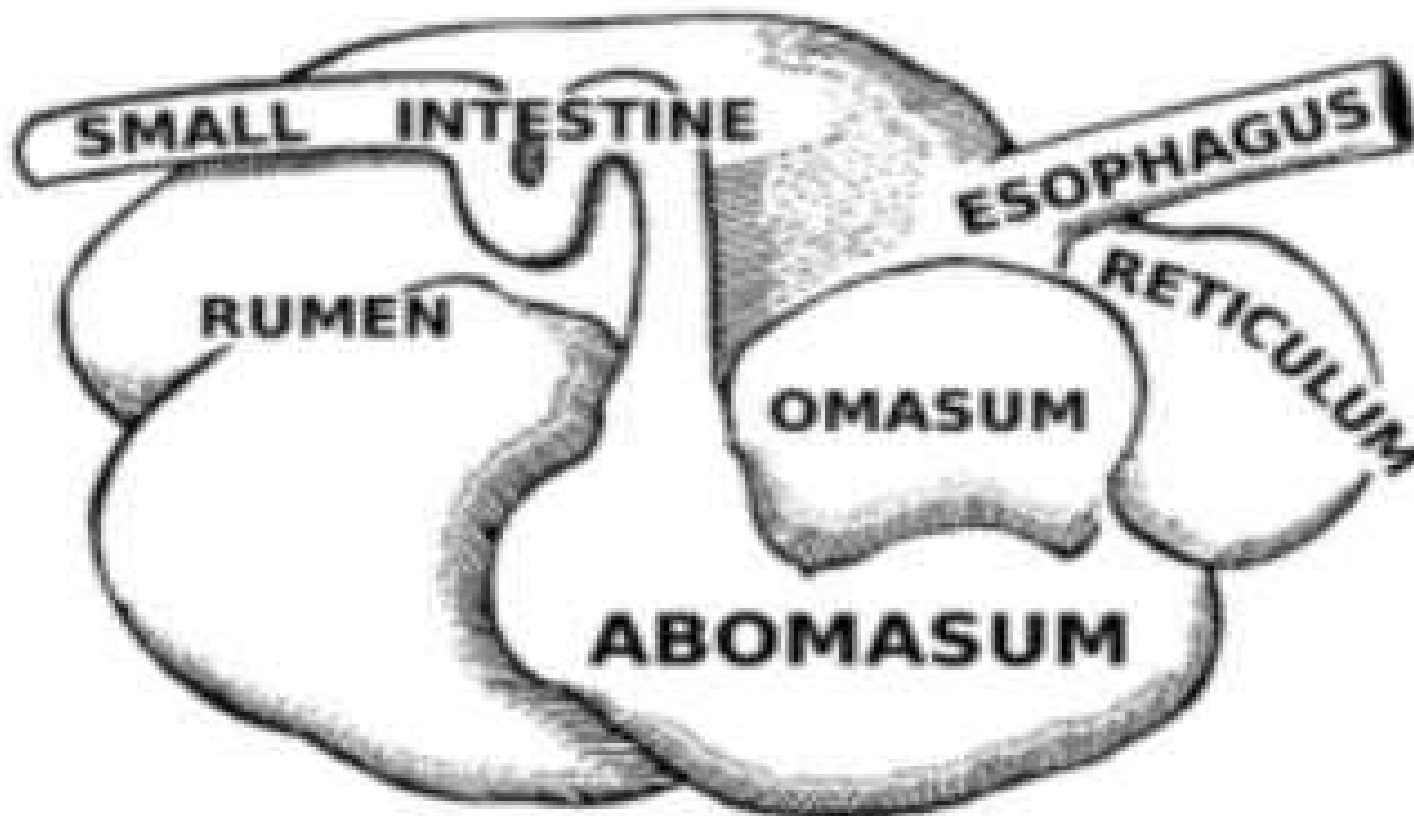
Stomach: The primary difference between ruminants and non ruminants is that ruminants have **4 chambered stomach** called compound stomach. The first three compartments that are rumen, reticulum & omasum are called **non secretory fore stomach** and fourth compartment i.e. abomasum known as secretory or true stomach.

- Fore stomach acts as **microbial fermentation vat** while abomasum is like the stomach of non-ruminants i.e. concerned with enzymatic digestion.

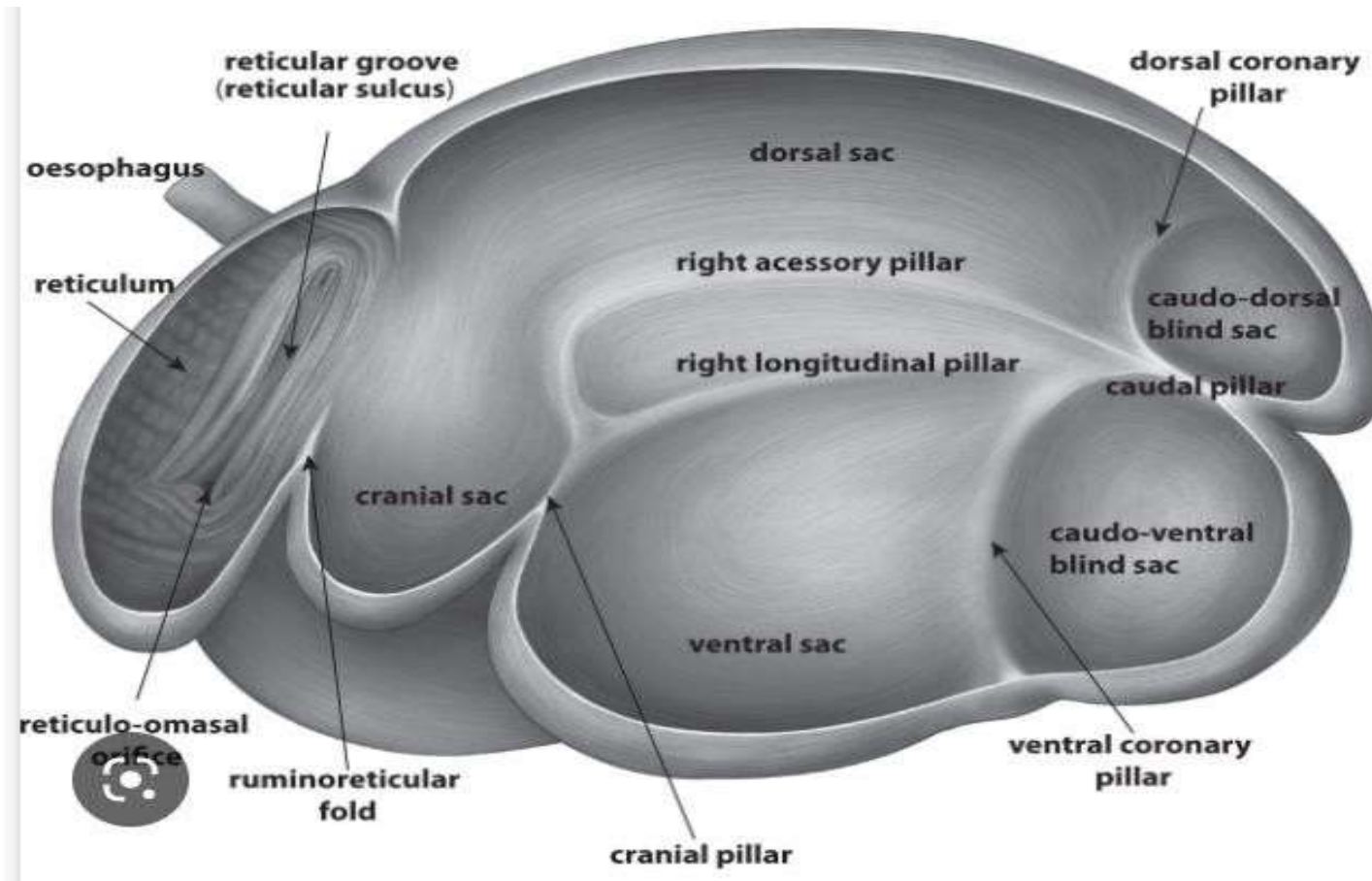
Rumen:

- First and largest compartment (70-80%) of compound stomach.
- Also known as **pouch**
- Divided into dorsal & ventral sacs by an incomplete partition formed by cranial & caudal muscular pillars and right & left longitudinal pillars.
- Located in the left side of abdominal cavity from diaphragm to pelvis.
- Dorsal part of rumen is divided into cranial sac, dorsal sac and caudo-dorsal blind sac.
- Turkish towel like appearance (**club shaped papillae**) on inner side of rumen.
- It communicates with reticulum by means of rumino-reticular opening.
- Esophagus opens at the **junction of rumen-reticulum** by cardiac opening.

Stomach of cattle



Stomach of cattle



Functions of rumen:

- Storage of food
- Churning of coarse fibrous food
- Proper mixing of ingesta
- Synthesis of vit B complex
- Microbial digestion of proteins, fats & carbohydrates
- Absorption of end products of microbial digestion i.e. VFA by ruminal wall.
- Expulsion of gases like CO₂ & CH₄

Reticulum:

- Second and smallest (5-7%) compartment of compound stomach.
- Spherical in shape which located behind diaphragm and opposite to heart.
- Inner side has **honey comb like** (hexagonal ridges) structure.
- Communicates with omasum by reticulo-omasal orifice.
- **Functions:**
- Separates foreign objects like wire, stones, nails etc from ingested food.
- Acts as a filter for the food material.
- Helps in regurgitation.

Omasum:

- **Elliptical or kidney shaped** that located on right side of abdominal cavity just behind reticulum.
- Forms 7-8% portion of ruminant stomach.
- Also known as manyplies.
- Inner surface contains almost 100 crescent shaped parallel folds called laminae that also bear small papillae that enhance the internal surface area for reabsorption.
- Communicates posteriorly with abomasum by omaso-abomasal orifice.
- **Imp. Function:** Absorbs VFA and water.

Abomasum:

- Also called true stomach because of **glandular structure** and like to simple stomach.
- Contains fundic, body and pyloric regions.
- Mucosa is arranged in about 12 high oblique folds within fundic and body of abomasum.
- Forms 7-8% of ruminant stomach.
- Situated on floor of abdominal cavity, ventral to omasum on right side of rumen.
- Communicates with duodenum by means of pyloric sphincter.
- **Function:** Secretes gastric juice which contains HCl and enzymes like pepsinogen and rennin.

Microscopic structure:

- Consists serosal, muscular and luminal layers.
- Esophagus has striated muscle through its entire length while stomach possesses only smooth muscle and distributed in layers in different directions.
- In fore stomach the luminal surface is **stratified squamous epithelium** with slight keratinization.
- In abomasum it is mucosal epithelium pitted with peptic glands.
- **Blood supply:** Fore stomach and most of abomasum are supplied via left gastric branch of celiac artery.
- Venous blood drains into hepatic portal vein and passes to liver before returned into caudal venacava by hepatic vein.
- **Nerve supply:** By vagal and splanchnic nerves both of which provide sensory and motor pathways.

Small intestine:

- Extends from pylorus to ilio-cecal junction.
- Divided into duodenum, jejunum and ileum.
- Average length is 50-52 meters in cattle.
- **Large intestine:** divided in cecum, colon and rectum.

Some imp. terms related to digestive system

- **Prehension:** it is the act of getting or seizing or grasping of food into oral cavity. Domestic animals do this by using their lips, teeth, tongue and head movement.
- It is a voluntary reflex and trigeminal, facial & hypoglossal nerves provide motor innervations to the lips, tongue and jaw muscles. Sensory information is derived from olfactory, optic and trigeminal inputs.
- Chief prehensile organs: Cattle: tongue, Horse: lips, Pig: snout. Dog: front legs & digits, Sheep: teeth, Camel: cleft upper lip
- **Mastication:** it involves the mechanical breakdown of food and allows mixing with saliva (insalivation). It is also under voluntary control. The tongue & buccal muscle position the food within mouth & teeth cut or grind the food. The trigeminal nerve (sensory input) to teeth and jaw muscles (motor input), facial nerve to tongue & pharynx (sensory & motor), glossopharyngeal nerve to tongue (sensory) and hypoglossal nerve to tongue (motor) are involved in mastication.

Swallowing or deglutition:

- It is a very complex process that occurs in three steps.
- **Oral phase:** first a bolus of food is pressed backward into pharynx by the tongue. It is the voluntary phase.
- **Pharyngeal phase:** once the bolus reaches the pharynx several actions are initiated which involve shunting the bolus into esophagus while at the same time closing of alternate route i.e. lumen of larynx squeezed, shut and epiglottis swings backward to cover the larynx. The larynx is also pulled forward & downward making opening of esophagus larger. In addition the swallowing centre in medulla inhibits respiratory centre by which respiration ceases.
- **Esophageal phase:** finally the tongue presses backward and a peristaltic contraction in pharynx propels the bolus into esophagus. In dog & human it takes 4-5 sec. for the bolus to traverse the esophagus. Sometime sec. wave of peristalsis are also initiated at the point of distension to deliver the bolus into stomach.

Rumination:

- It is the process by which the ruminant regurgitates the previously consumed feed and remasticate, reinsalivation & reswallowing it a second time. It is the process of **chewing the cud**.
- **Mechanism:** Triphasic contraction of the reticulum that forces digesta to the cardia.
- Animal inhales with closed epiglottis that produces a vacuum of 60-80 mm of water in esophagus.
- Cardiac sphincter opens and esophagus dilates by which negative pressure sucks the digesta into esophagus.
- Rapid reverse peristalsis moves the digesta toward mouth.
- Bolus is rechewed slowly & more deliberately than during eating.
- Digesta are insalivated in which parotid glands secrete more HCO₃ secretion. Reswallowing and rumen undergoes a primary contraction to move it back in the rumen and released in a fine state that will not return to mouth again.
- **Rumination time:** average time for grazing animal is 8 hrs.
- **Factors affect the rumination:** fibre content and physical form of diet (Increasing grain proportion in diet decreases rumination while increasing mature forages in diet increases rumination).

Defecation

- It is the final act of digestion, by which organisms eliminate solid, semisolid, or liquid waste material from the digestive tract via the anus.
- The rectum ampulla (anatomically also: *ampulla recti*) temporarily stores fecal waste. As the waste fills the rectum and expands the rectal walls, nervous system stretch receptors in the rectal walls stimulate the desire to defecate. This urge to defecate arises from the reflex contraction of rectal muscles, relaxation of the internal anal sphincter, and an initial contraction of the skeletal muscle of the external anal sphincter. If the urge is not acted upon, the material in the rectum is often returned to the colon by reverse peristalsis, where more water is absorbed and the faeces is stored until the next mass peristaltic movement of the transverse and descending colon.

- When the rectum is full, an increase in intra-rectal pressure forces apart the walls of the anal canal, allowing the fecal matter to enter the canal. The rectum shortens as material is forced into the anal canal and peristaltic waves push the feces out of the rectum. The internal and external anal sphincters along with the puborectalis muscle allow the feces to be passed by muscles pulling the anus up over the exiting feces.
- Defecation is normally assisted by taking a deep breath and trying to expel this air against a closed glottis. This contraction of expiratory chest muscles, diaphragm, abdominal wall muscles, and pelvic diaphragm exerts pressure on the digestive tract. Ventilation at this point temporarily ceases as the lungs push the chest diaphragm down to exert the pressure. Thoracic blood pressure rises and as a reflex response the amount of blood pumped by the heart decreases. During defecation, the external sphincter muscles relax. The anal and urethral sphincter muscles are closely linked that's why defecation is frequently accompanied by urination.

Vomition:

- Vomiting is the forceful expulsion of contents of the stomach and often, the proximal small intestine.
- It is a manifestation of a large number of conditions, many of which are not primary disorders of the gastrointestinal tract.
- It can have serious consequences as acid-base derangements, volume and electrolyte depletion, malnutrition and aspiration pneumonia.
- **The Act of Vomiting:** Vomiting is usually experienced as the finale in a series of three events as nausea, retching & emesis.

Nausea

- It is an unpleasant and difficult to describe psychic experience.
- Physiologically, nausea is typically associated with decreased gastric motility and increased tone in the small intestine. Additionally, there is often reverse peristalsis in the proximal small intestine.

Retching

- **Retching** ("dry heaves") refers to spasmodic respiratory movements conducted with a closed glottis. While this is occurring, the antrum of the stomach contracts and the fundus and cardia relax.

Emesis or vomiting

- It is when gastric and often small intestinal contents are propelled up to and out of the mouth. It results from a highly coordinated series of events that could be described as the following series of steps:
 - A deep breath is taken, the glottis is closed and the larynx is raised to open the upper esophageal sphincter. Also, the soft palate is elevated to close off the posterior nares.
- The diaphragm is contracted sharply downward to create negative pressure in the thorax, which facilitates opening of the esophagus and distal esophageal sphincter.
 - Simultaneously with downward movement of the diaphragm, the muscles of the abdominal walls are vigorously contracted, squeezing the stomach and thus elevating intragastric pressure. With the pylorus closed and the esophagus relatively open, the route of exit is clear.

- The series of events described seems to be typical for humans and many animals, but is not inevitable. Vomition occasionally occurs abruptly and in the absence of premonitory signs - this situation is often referred to as *projectile vomiting*. A common cause of projectile vomiting is gastric outlet obstruction, often a result of the ingestion of foreign bodies.
- An activity related to but clearly distinct from vomiting is *regurgitation*, which is the passive expulsion of ingested material out of the mouth - this often occurs even before the ingesta has reached the stomach and is usually a result of esophageal disease.
- **Regurgitation is a normal component of digestion in ruminants.**
- There is also considerable variability among species in the propensity for vomition. Cattle and horses vomit rarely - this is usually an ominous sign and most frequently a result of acute gastric distension. Carnivores such as dogs and cats vomit frequently, often in response to such less important stimuli as finding themselves on a clean carpet.

Developmental aspects of digestion in ruminants (ecological development):

- The hoofed mammals (ungulates) are the chief group of large grass eating herbivores. These have a symbiotic relationship with suitable microbes through the development of specialized structures that serve as fermentation chamber for microbial digestion by which major carbohydrates of grasses become available to these animals. For eg.-
- In odd toed ungulates (horse) fermentation vat is the enlarged cecum and colon that receive digesta after GI digestion but this device seems inefficient.

- In even toed ungulates (pig & hippopotamus) that represent a small transitional group in which enlarged cecum & colon plus non-secretory large fermentative portion in enlarged stomach so that pregastric fermentative digestion also takes place.
- In tylopoda (camel), there is development of more complex forestomach in which forestomach has 2 interconnecting chambers i.e. rumen & reticulum but lacks omasum in addition to secretory stomach (abomasum) sometimes named chamber Ist, IInd and IIIrd of stomach. These animals cud the chew (rumination), canines teeth are primitive & grouped as **pseudo ruminant**.
- Even toed ruminants (bovines) that have complexed 3 chambered forestomach in addition to secretory stomach (abomasum) and have unique dentition in which upper incisors & canines are absent and space is occupied by dental pad while lower canines have joined with incisor in form of incisor teeth. These animals are true ruminants continue to be most successful large grass eating mammals in which 68 genera still exists among which 4 genera have main domestic species.

Classification of main domestic species

Kingdom	Animalia						
Phylum	Chordata						
Class	Mammalia						
Order	Perisodactyla (odd toed, hoofed, non-ruminant)		Artiodactyla (even toed, hoofed)				
sub-order	Hippomorpha	Suina	Tylopoda	Ruminantia			
Family	Equidae	Suidae	Camelidae	Bovidae (hollow horn ruminants)			
Genus	Equus	sus	Camelus	Bos	Bubalus	Ovis	Capra
Spp.	E. caballus (Horse)	S. scrofa (Pig)	C. dromedarius (single hump camels), C. bactrianus (double hump camels)	i. B. taurus (European cattle) ii. B. indicus (Indian cattle)	B. bubalis (water buffalo/Asian buffalo) sub spp. a. B. bubali bubalis (River buffalo) b. B. bubalis carabanesis (Swamp buffalo)	O. aries (sheep)	C. Hircus (goat)
Remark	fermentation vat is the enlarged cecum and colon	enlarged cecum & colon plus non-secretory large fermentative portion in stomach	complex forestomach has 2 interconnecting chambers rumen & reticulum but lacks omasum in addition to secretory stomach (abomasum)	complexed 3 chambered forestomach in addition to secretory stomach (abomasum)			

Ecological benefits of ruminant digestion:

- The ecological success of ruminant digestion is due to pregastric (fore stomach) fermentation as-
- This allows the utilization of fibrous diet i.e. not suitable for non-ruminants.
- This confers the ability to break down cellulose & related compounds.
- This allows the synthesis of high biological value microbial proteins (rich in essential amino acids) from low biological value plant proteins from dietary NPN substances.
- This confers the microbial synthesis of all components of vit-B complex.

Development of the Calf Digestive System: four stages

- **1. New born phase (colostral phase):** This phase lasts for 24 hours afterbirth. The newborn animals have the same forestomach as an adult but the rumen is significantly smaller in size and contains no microbial population.
- The papillae present in the rumen are also rudimentary.
- In the calf, the largest part of the digestive tract is the abomasums (fourthstomach), making up nearly 70% of the digestive tract. At this point, the immature digestive metabolic systems function similarly to those of a young mono gastric animal.
- At this period the only diet is colostrum (the first milk) which contains a high level of immunoglobulins.
- The abomasums doesn't secret acid or pepsinogen thereby undigested immunoglobulins pass it and reach in intestine.
- The intestine also can't affect them due to the presence of anti-trypsin in colostrum. As a result, the antibodies present in the colostrum are absorbed directly from the intestine and goes to the blood.
- This provides natural passive immunity to the new born animal.
- This is very important as it helps in gaining disease resistant power. But, this direct absorptive capacity of intestine e remains for only 24-48hours after birth and disrupted if milk is provided. So, only colostrum should be fed to the newborn.
- If proper colostrum feeding is not done, there will be a decline in immunity. It can result in acute infection like "joint-ill" and "naval-ill"

2. Pre-ruminant digestion:

- This period lasts from one day to 21 days (3 weeks).
- The principal food for this period is milk or milk replacer as an easily digestible source of carbohydrate and protein, though in the later part of this phase solid feed is also taken.
- The act of sucking by the calf causes a fold of muscle to develop in the wall of the rumen called the reticular or esophageal groove. In the young pre-ruminant, during nursing, the reticular groove serves as a passageway for milk from the esophagus to the omasal canal and abomasum. Closure of the reticular groove is a reflex initiated by suckling or drinking. As the calf sucks, the esophageal groove delivers milk directly to the abomasum where it is digested most efficiently.
- Suckling of milk also promotes the secretion of saliva.
- Saliva contains an enzyme called esterase which promotes hydrolysis of milk lipids. But, this milk bypasses the rumen and reticulum and directly goes to the abomasum.
- It stimulates the secretion of the abomasum and further digestion of milk components.
- In the first weeks of life, rennin is the predominant enzyme in the digestive system of the calf. Rennin allows the calf to efficiently utilize the proteins in milk. In time, as the level of the enzyme pepsin increases, the calf is able to utilize non-milk sources of protein. For this reason, milk replacers that contain non-milk protein should not be fed to the calf in the first three weeks of life. For the first three to four weeks of life the enzyme lactase also predominates, meaning the calf can effectively utilize lactose, the important carbohydrate in milk. The calf is unable to utilize starch at this stage.

The transition phase (development of the digestive system):

- The transition phase (period covering the move from the pre-ruminant to the ruminant phase) occurs between four and eight weeks of age, when the rumen begins to take over the main digestion of feed.
- When a calf consumes water and starter concentrates, bacterial fermentation is initiated in the rumen. This generates large amounts of Volatile Fatty Acids (VFAs) in the forms of acetate, butyrate and propionate.
- This production of VFAs is responsible for rapid rumen development. The time it takes for the calf to change from using just the abomasum to efficiently using all four stomachs depends on the type of food it is fed.
- If milk is freely available for a long time, the calf will have only a small appetite for dry feeds and rumen development is slow. If the feed management encourages the calf to eat solid feeds, rumen development is enhanced and the calf reduces its dependence on liquid milk as a source of essential nutrients.
- By one week of age the calf should be encouraged to eat some concentrates and hay/straw. If the calf is on a restricted liquid diet and has access to solid feed, this transition from pre-ruminant to ruminant digestion can be completed at about six weeks of age.

4. Ruminant digestion:

- Ruminant digestion is based on the function of the rumen, where micro-organisms transform carbohydrate, protein and all other fermentable substances into volatile fatty acids, ammonia, methane, carbon dioxide and microbial protein. The ruminant phase begins at about six to eight weeks of age. At this point, dry feed is the sole source of feed, and the rumen accounts for approximately 70% of all stomach compartments. A calf will usually have full rumen development at 12 weeks of age and its ability to eat and digest dry food will then be more or less similar to that of an adult animal.

Table 5. The proportions of the compartments of the stomach of grazing lambs as percentages of the weight of the whole stomach

Swenson (1984)

Age (days)	Rumen and reticulum	Omasum	Abomasum	Whole stomach as percentage of whole alimentary tract
1	31	8	61	22
14	36	5	59	25
30	63	5	32	27
49	71	5	24	35
112	73	6	21	39
Adult	69	8	23	49

Ingredients to initiate rumen development:

- Rumen development is defined as the development of the epithelium and it is critical to successful weaning and good calf growth rates. There are five key ingredients that are required to initiate rumen development:
- **I. Bacteria:** Rumen bacteria are absent when a calf is born and are introduced as the calf begins to eat calf starter concentrates. Bacteria help the digestive process. Bacterial end products of digestion (VFAs) cause significant changes in the rumen. The type of VFA produced is crucial. Calf starter contains carbohydrates in the form of starch which is fermented by bacteria that produce propionic and butyric acids. In contrast, when forages are digested the primary end product is acetic acid.
- Acetic and propionic acids are absorbed through the rumen wall and are converted into metabolites that the calf uses as energy sources. Butyric acid is not absorbed through the rumen wall and is instead converted into an energy source used by cells in the rumen wall.
- The production of VFAs lowers the pH of the rumen and establishes an ideal growing environment for bacteria, especially for bacteria that digest starch and produce propionic and butyric acids.

II. Liquid in the rumen:

- Liquid in the rumen provides an ideal environment, combined with the absence of oxygen, for the rapid growth of bacteria. As milk bypasses the rumen, it does not provide enough liquid for optimal rumen development and therefore the calf must have access to „free water“ (see chapter 14). Offering water from three days of age helps to increase calf weight gain, promotes starter intake and reduces the incidence of scour.
- **III. Muscular movement:** Outflow of material from the rumen Feedstuffs that enter the rumen must be able to leave it. Therefore the development of rumen activity, such as contractions, pressure and regurgitation, is necessary. This muscular movement also helps mix the feedstuffs. When the calf is born, the rumen has little muscular activity, few contractions and no regurgitation. As the calf's dry feed intake increases, rumen contractions begin. If calves are fed milk, hay, and starter from shortly after birth, normal rumen contractions can be detected as early as three weeks of age. In contrast, if calves are only fed milk, normal rumen contractions may not be measurable for extended periods.

IV. Absorptive ability of the tissue:

- From a structural point of view, the rumen is made up of two layers: the muscular and the epithelial, the latter is responsible for absorption of VFAs. At birth, the epithelium does not have any ability to absorb. It is the production and subsequent absorption of VFAs in the rumen, from the fermentation of starter feedstuff that stimulates epithelium development by increasing the surface area through the development of the epithelium into finger-like projections called papillae.
- **V. Availability of feed stuff in the rumen:** The key factor to promote early rumen development, and thereby early weaning, is dry feed intake. As concentrates are fermented to propionate and butyrate, they are a good choice to ensure early rumen development. Offer clean, fresh, starter at three days of age which is both highly palatable and meets the nutrient recommendations for dairy beef calves.

In nutshell:

- At birth the **abomasum** is the largest compartment of the ruminant stomach, and the type of the diet in ruminant neonates is similar to that in the omnivorous and carnivorous adults.
- As the newborn ruminant matures, it gradually increases intake of roughage, and the reticulum, rumen, and omasum grow rapidly and reach adult proportions at about 6-12 months of age. Lambs and calves will show an interest in hay or grass at 1-2 weeks of age and begin to consume small quantities of a few bites at a time. Along with increased intake of roughage, increased relative capacities of the rumen and reticulum are found. An increase in rhythmic contractions of the first three compartments of the stomach accompanies increased fermentation and anatomical growth. Brief periods of rumination may be observed in calves as early as 2-3 weeks of age.
- Young ruminants fed only milk diets do not develop normal capacities, motility patterns, or papillae in the rumen. Papillary development is not stimulated by mechanical action of bulky materials inserted into the rumen of milk-fed animals; however, short chain fatty acids (SCFA) have been found to encourage papillary development in the stomach. Possibly, the stimulatory effect of the SCFA results from metabolism of the acids in the rumen epithelium. In the mature ruminant the rumen is the largest compartment of the stomach. Liquids and food enter through the relative small cardiac opening, which is usually submerged in the ingesta. Extensive absorption of nutrients occurs in the first three compartments. All unabsorbed residues are pushed from the ruminoreticulum into the omasal canal through the reticulo-omasal opening. The rumen is a multicompartiment structure that opens cranially to the reticulum over the ruminoreticular fold.

THANKS