

# MJF COLLEGE OF VETERINARY & ANIMAL SCIENCE CHOMU JAIPUR

---

TOPIC. DISBUDDING




---

# DEHORNING AND DISBUDDING



- **DISBUDDING**

---

- Removing the very early developing horn base to prevent horn growth
  - Removal of horn buds
  - Age - 3-6 weeks
  - this age horn buds are button like & easy to move
- 

- **Indication**

---

- Easy & safe restraint of the animal
- Reduce of the risk of injury
- Aesthetic purposes in show animals (not in Buffalo )

# PROCEDURE OF DISBUDDING

---

- Disbudding is painful & stressful procedures
- Cornual nerve block with local anesthetic
- Two methods

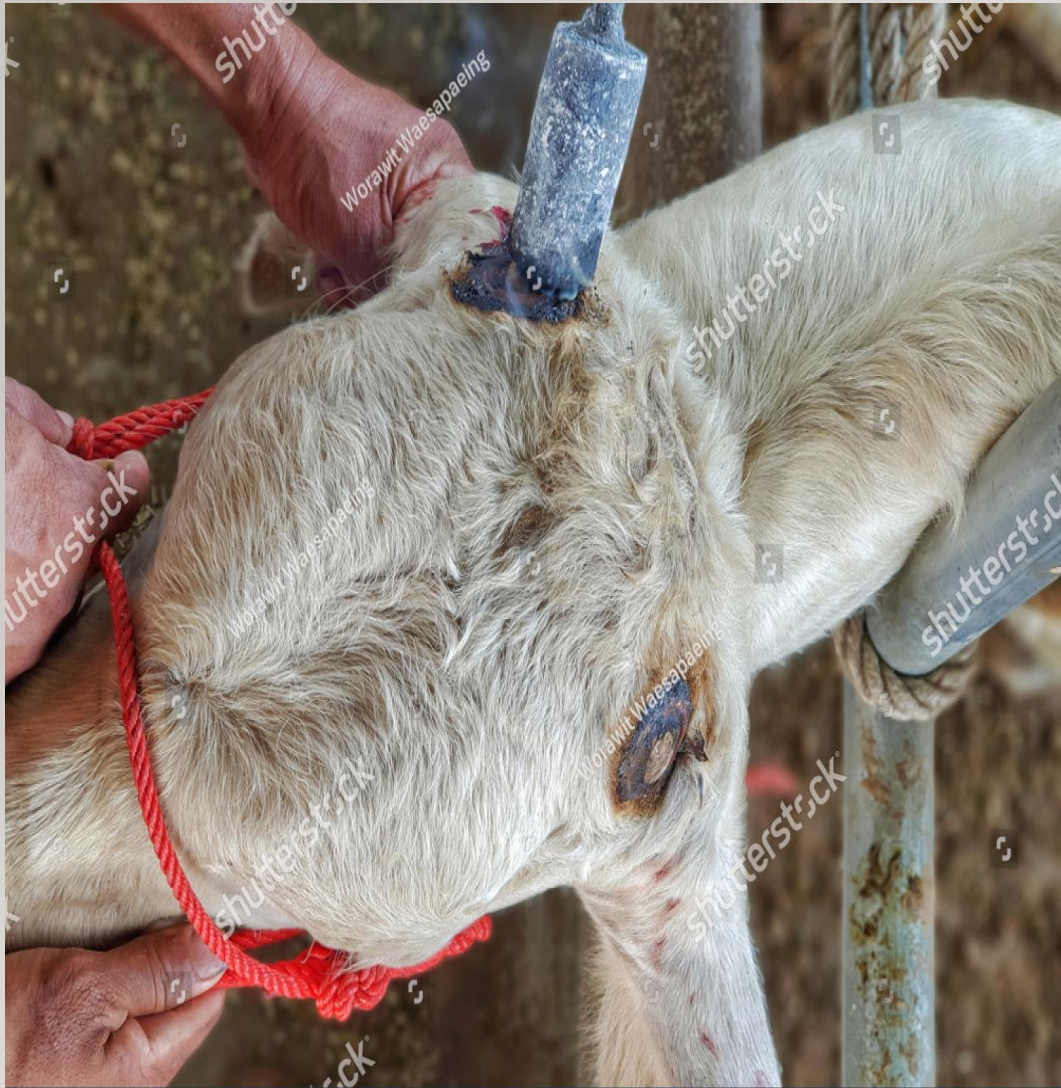

- I. **Thermal** – use of circular hot iron to cauterize the tissue around the base of the horn -after removing the hair around the bud - Hot iron should be put over the bud & twist around for about 10 sec

- Care should be taken not to use too much pressure or forceful use Especially with goat kids because of small sized thinner skull
- 

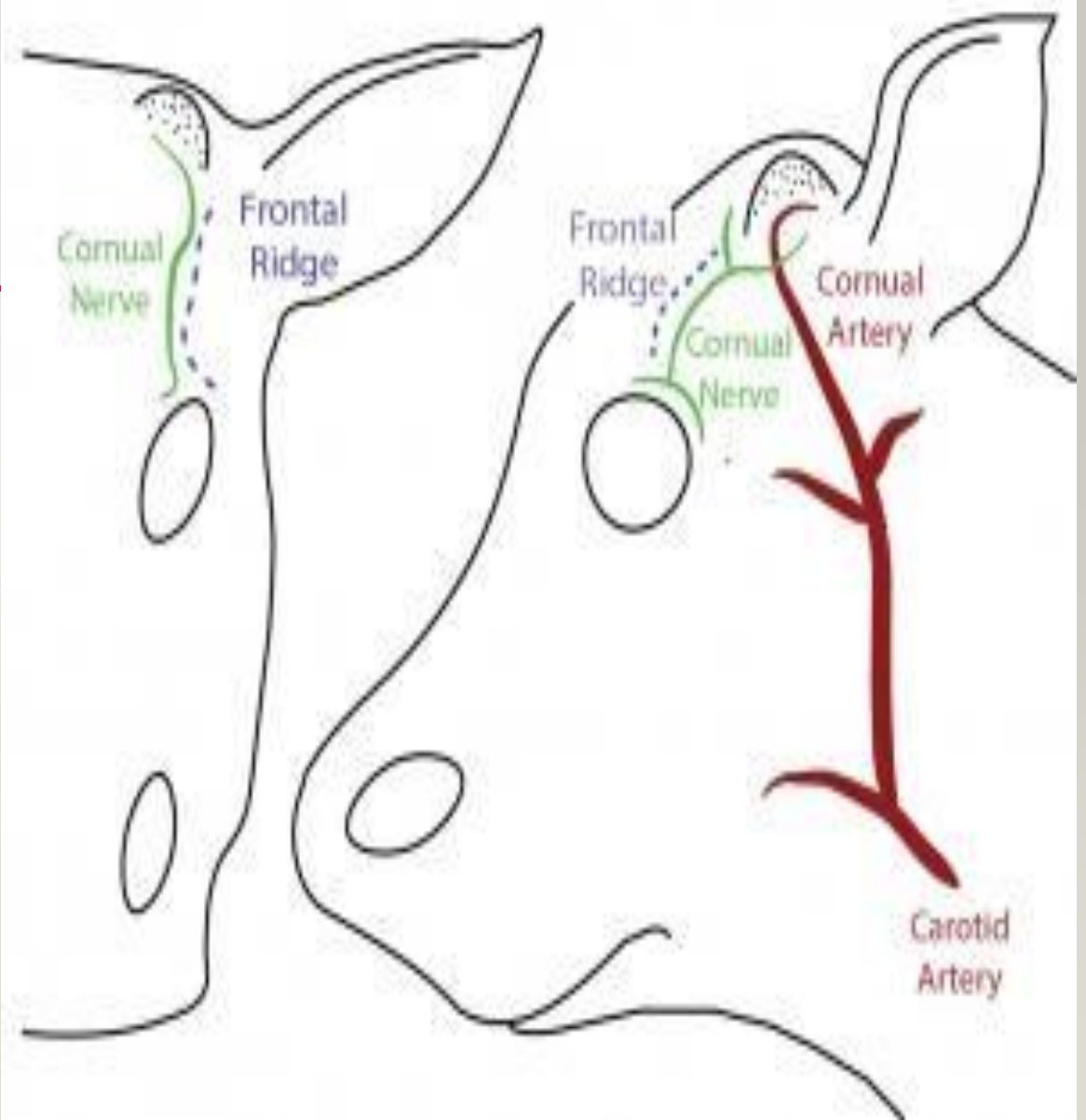
- **Chemical**

- Age 1- 7 day
- Using Caustic soda to remove the buds
- Cause chemical burns to permanently damage the horn producing area



shutterstock

IMAGE ID: 1250508781  
www.shutterstock.com



# DEHORNING

---


- In adult animals
- Following overgrown situations & injuries & affected horn
- This procedure is not painful
- Flap method described angelo and Das (1970)



# DEHORNING PROCEDURE

- Hairs around the base of horn - cleaned & clipped
- Block the cornual nerve block with 2% lignocaine hydrochloride-  
reduces pain
- An elliptical incision is given around the base of horn & skin both sides of incision is reflected to form a flap.
- Ligation of cornual artery – bloodless operation
- Now cut – wire saw
- Skin flaps – mattress sutures - protective bandage –next day ligature remove





THANK YOU

