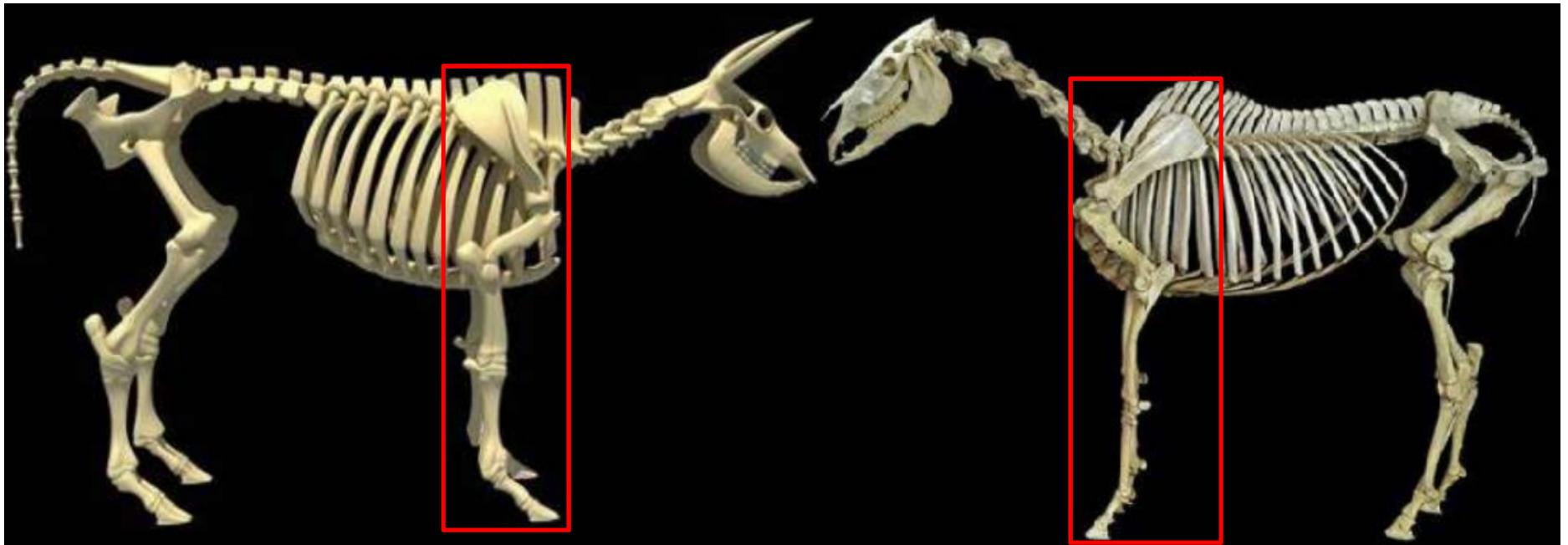
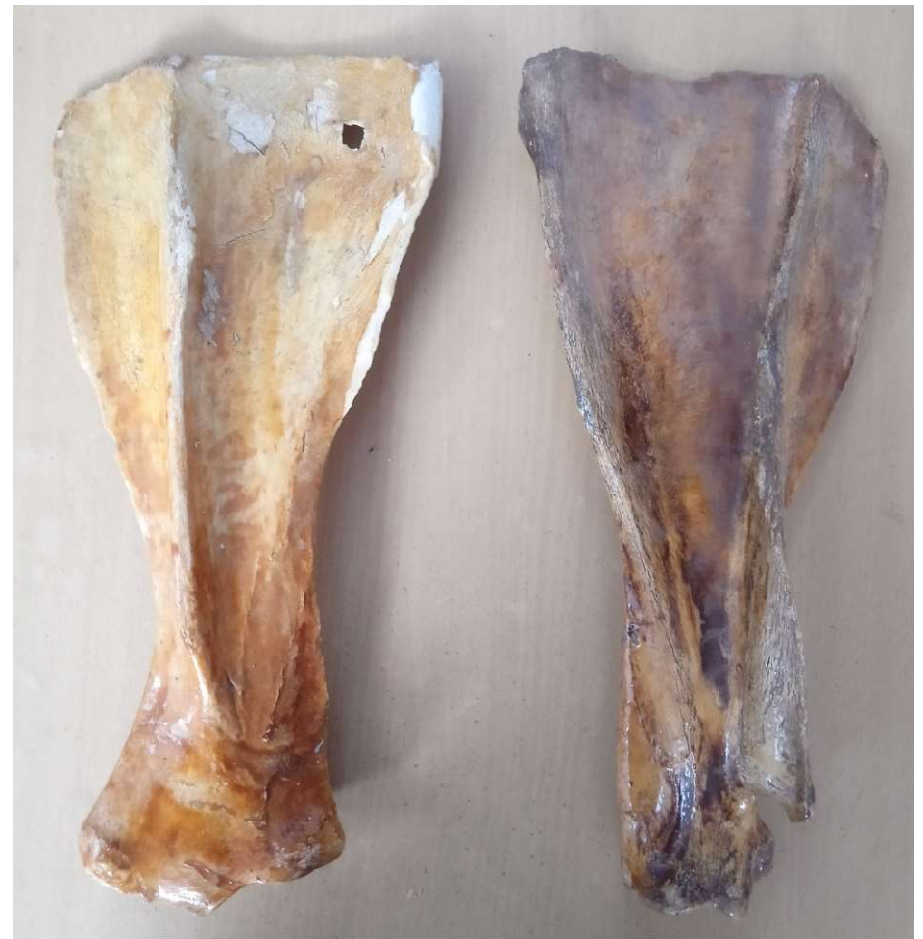

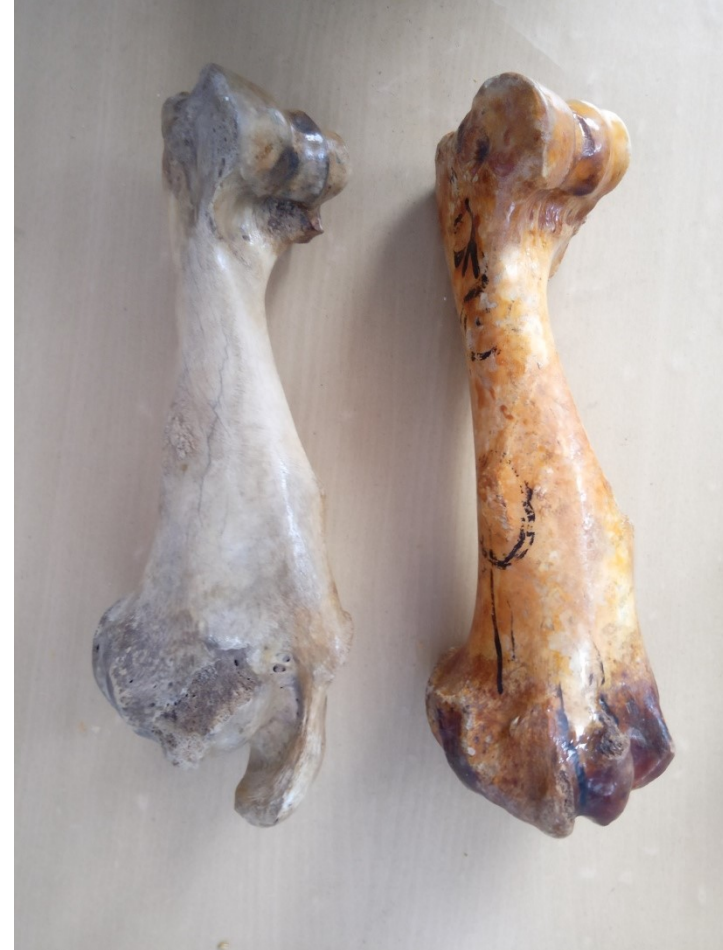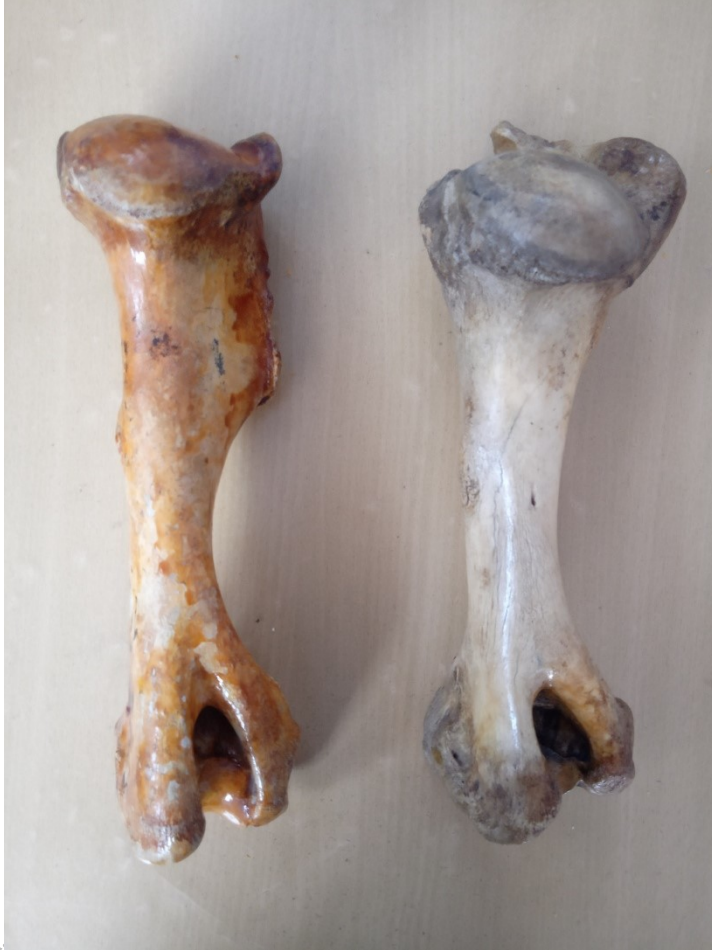# STUDY OF BONES OF FORE LIMB



# SCAPULA (Ox & Horse)



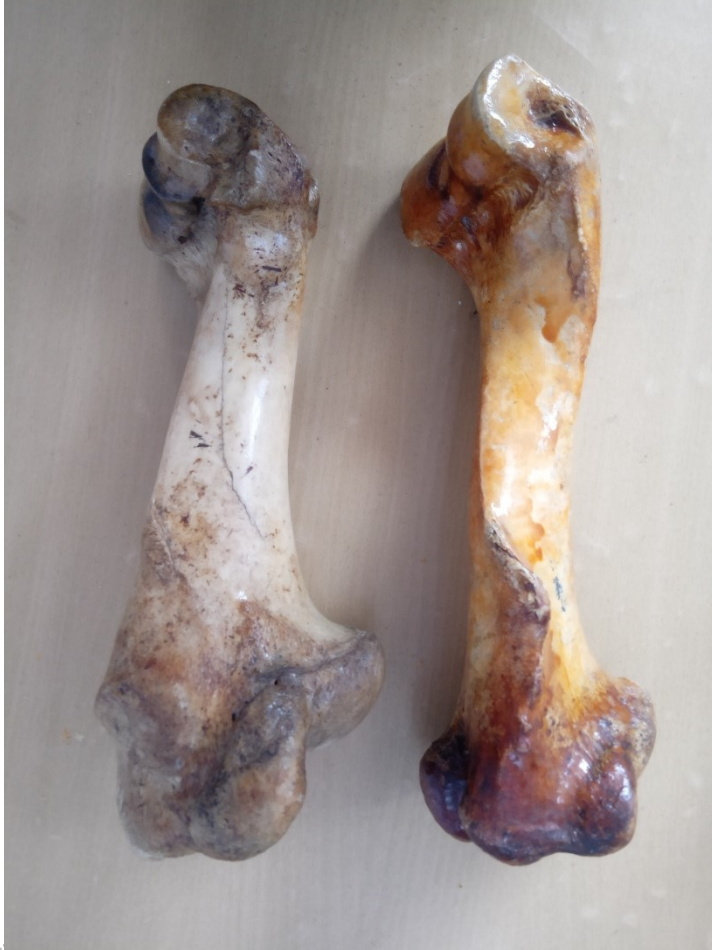# HUMERUS (Ox & Horse)



Dr. K

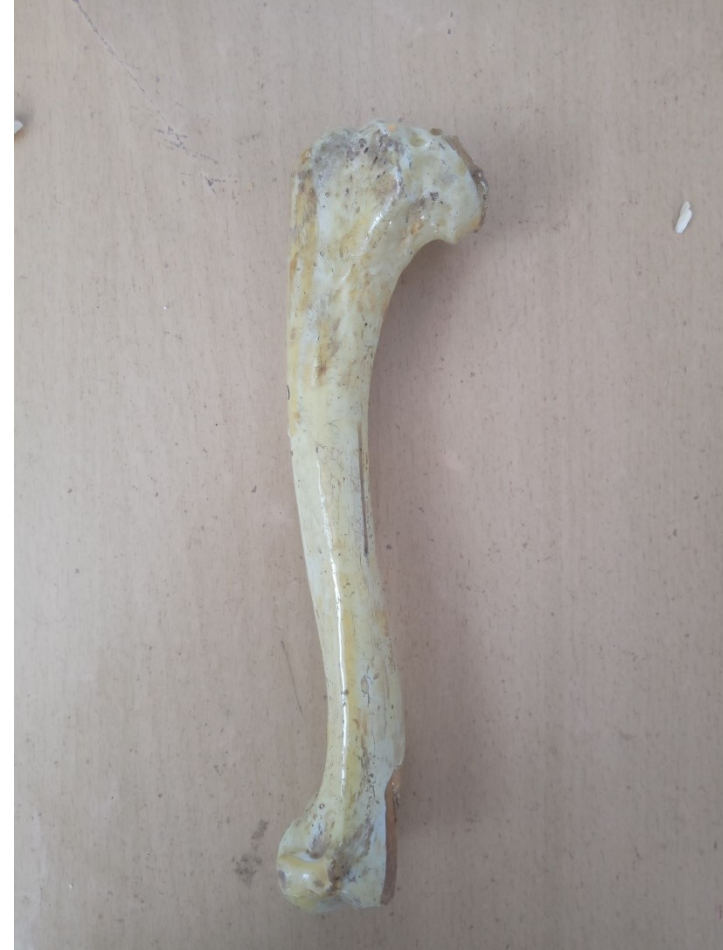

# HUMERUS (Ox & Horse)



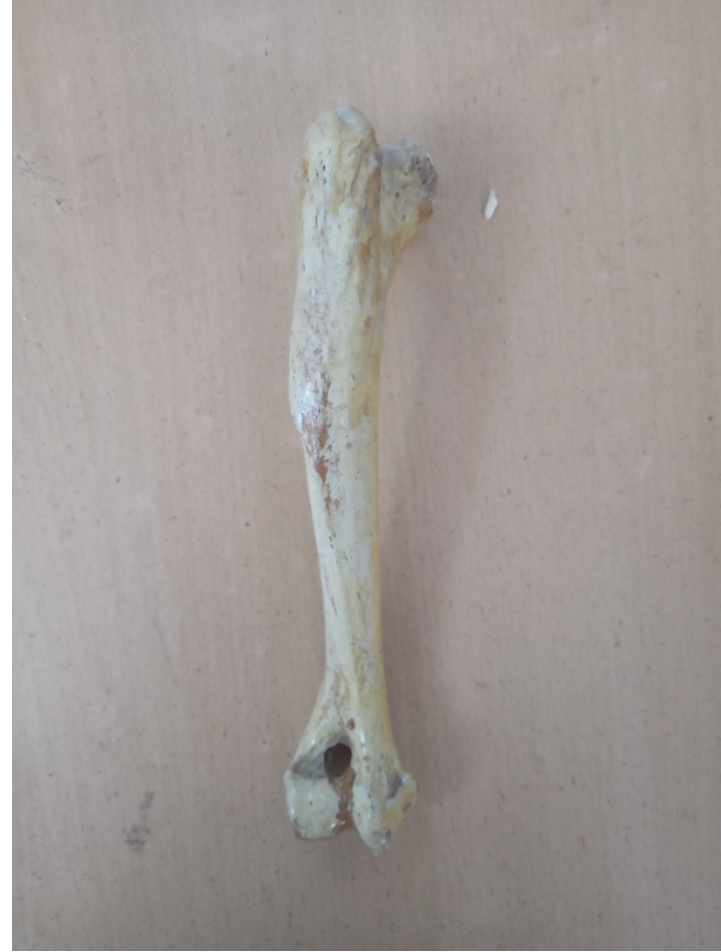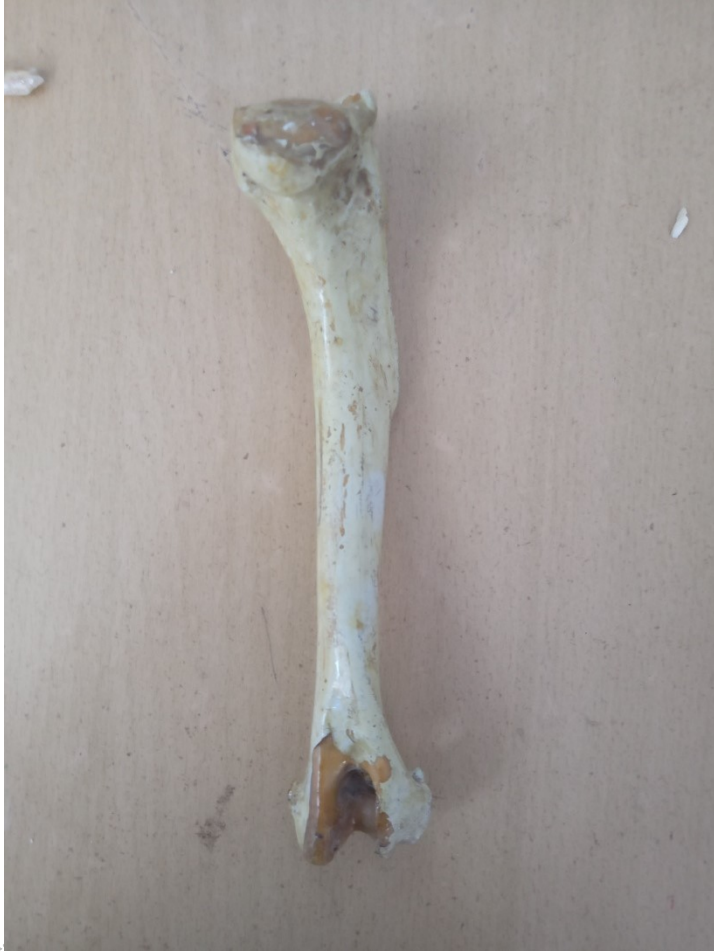Dr. K

# HUMERUS (Dog)



Dr. K

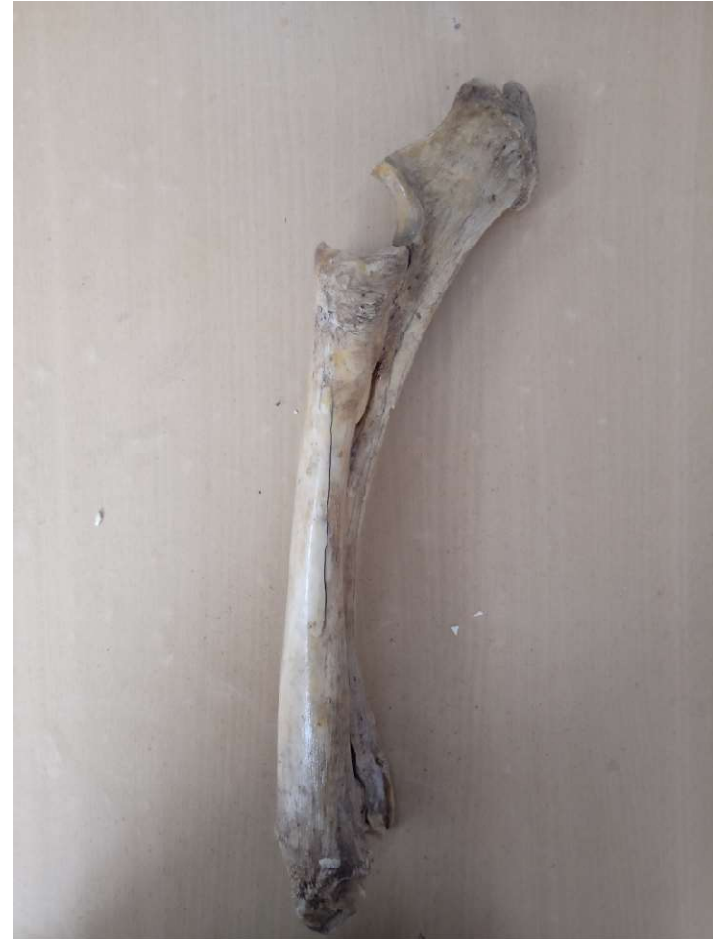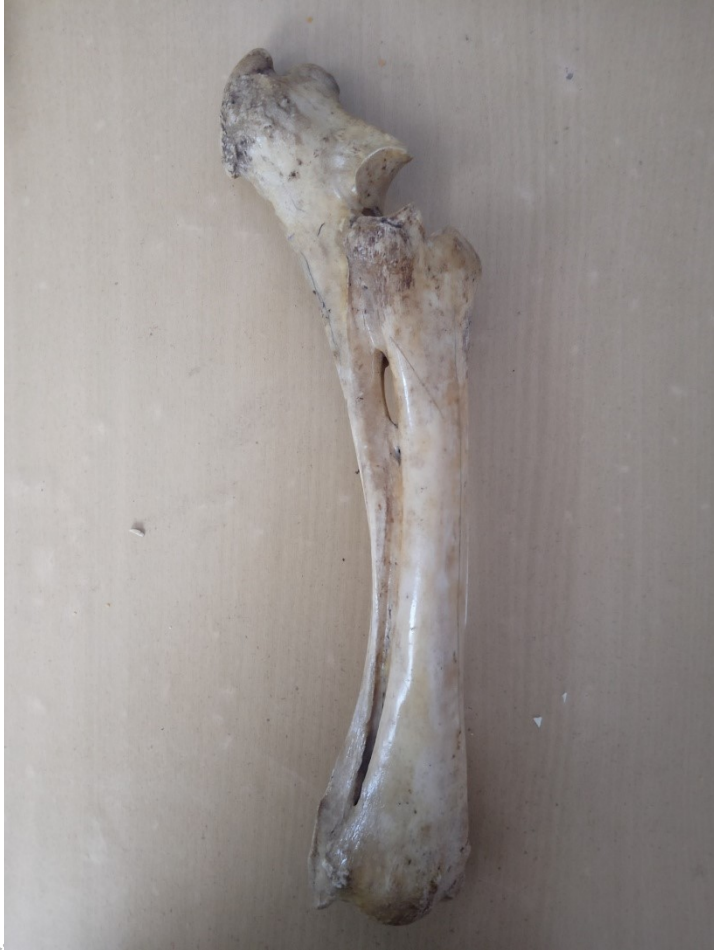# HUMERUS (Dog)



Dr. K

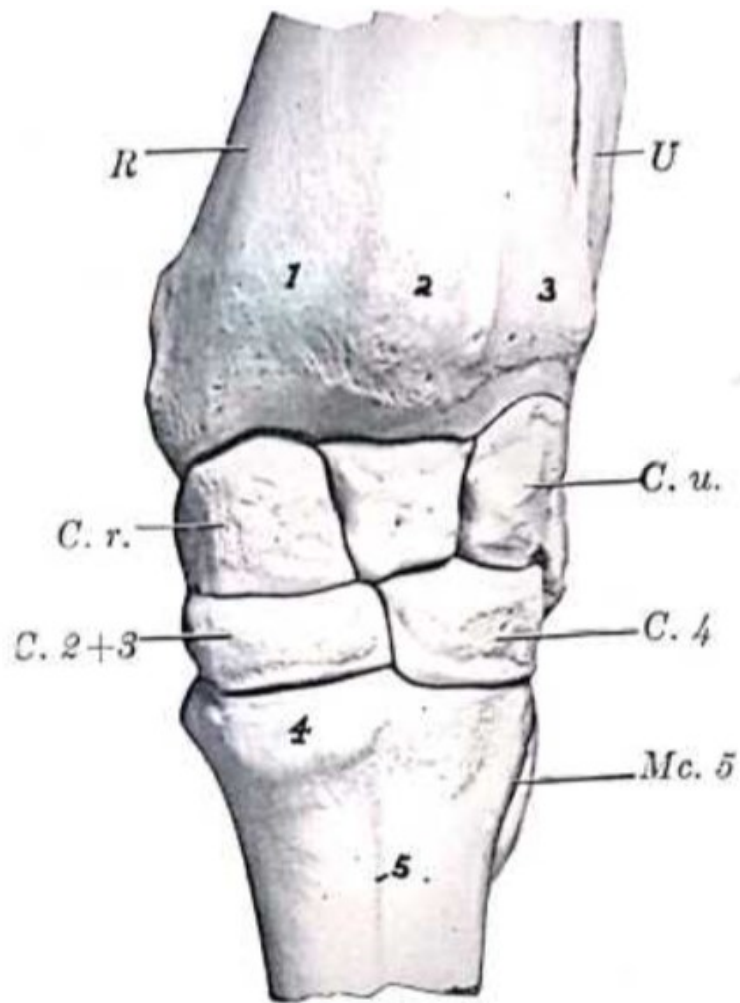


# RADIUS & ULNA (Ox)

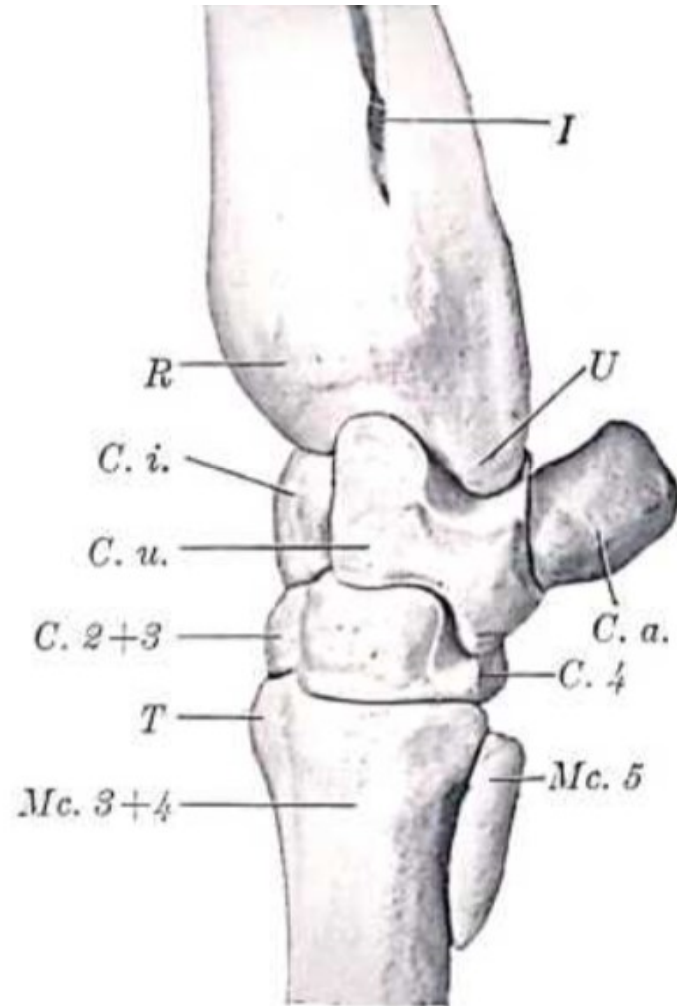


Dr. K

# CARPAL BONES



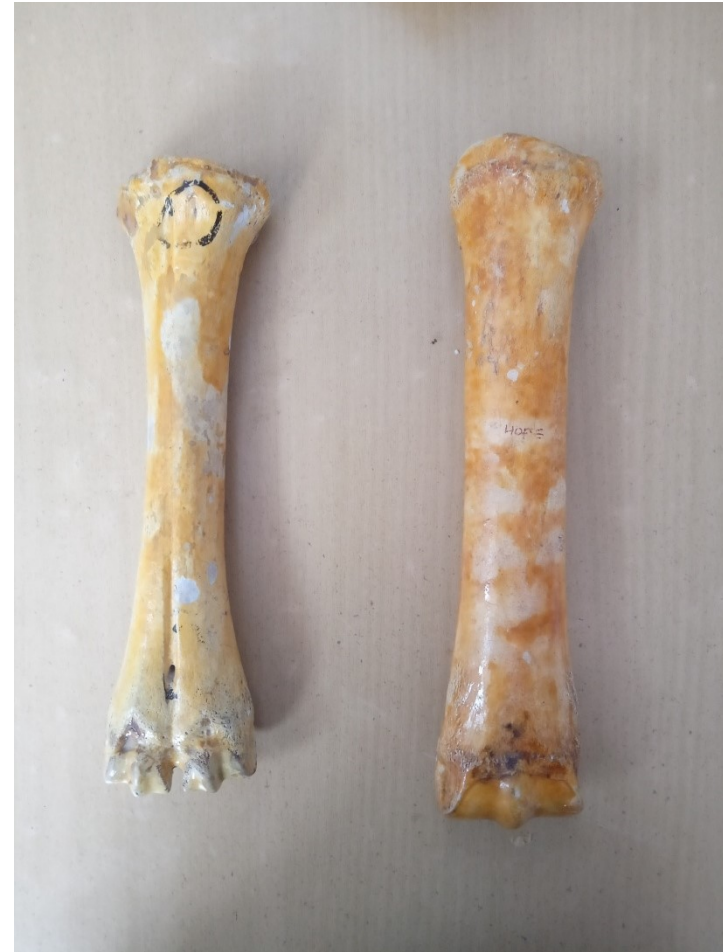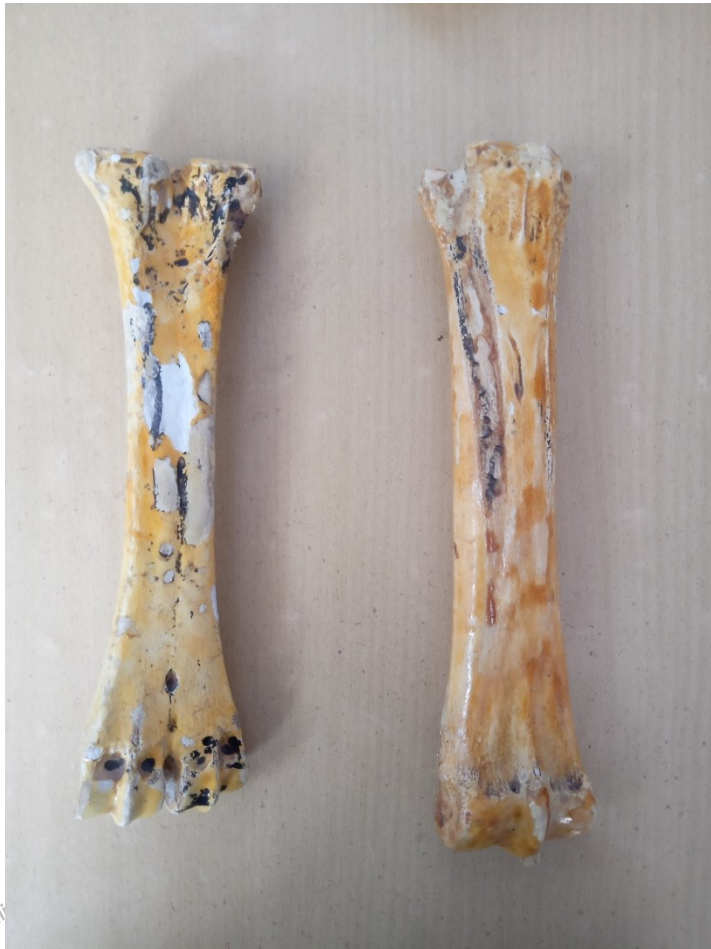—LEFT CARPUS AND ADJACENT BONES OF OX;  
FRONT VIEW.



—LEFT CARPUS AND ADJACENT BONES OF  
OX; LATERAL VIEW.

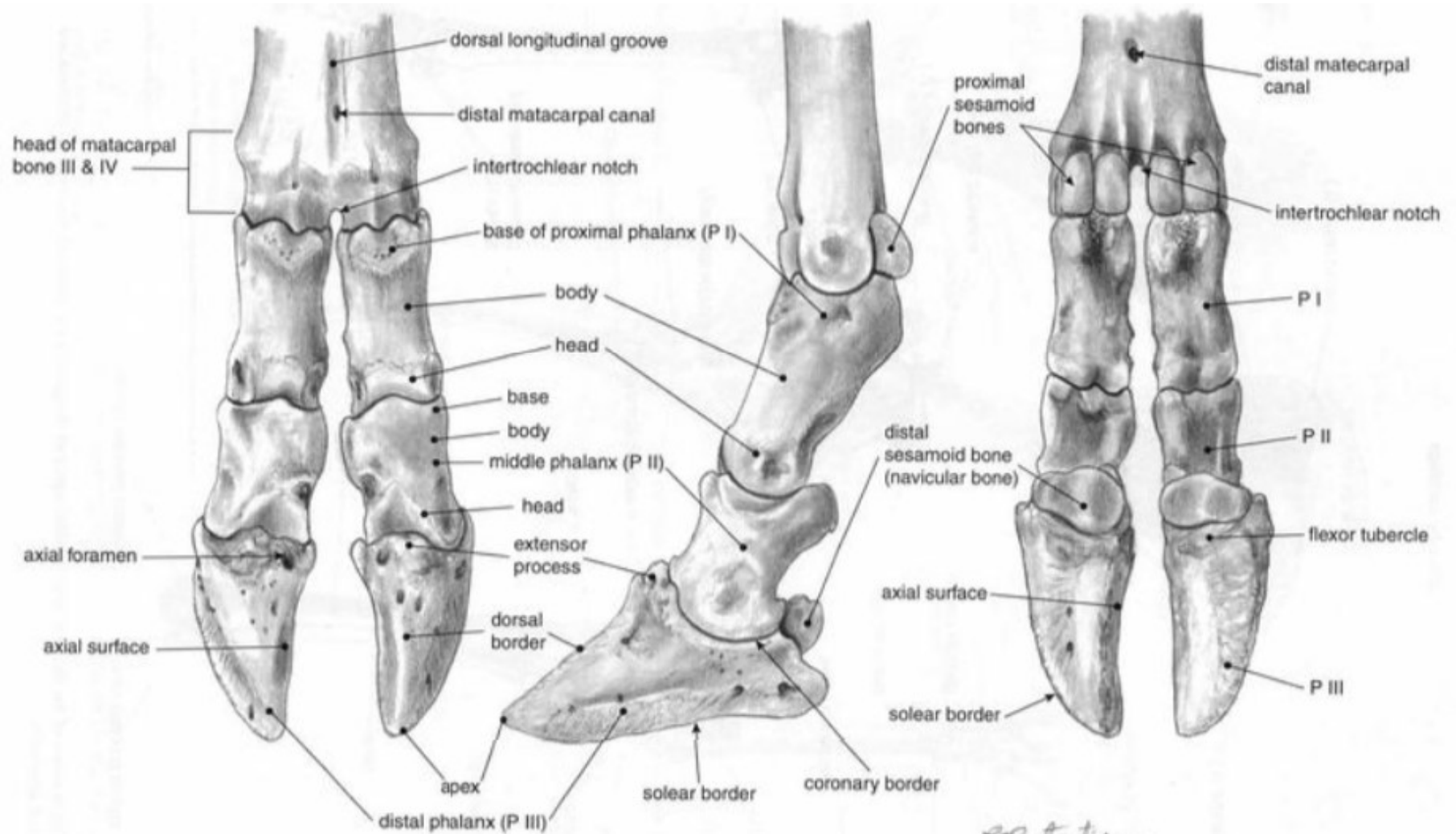

# METACARPAL BONES (Ox & Horse)



Dr. K. Kalita

# PHALANGES



# Thank You

*Dr. K. Kalita; MVSc*

*Dr. K. Kalita; MVSc*